

Anatomy & Physiology

for Speech, Language,
and Hearing

SIXTH EDITION

J. Anthony Seikel, PhD
David G. Drumright, BS
Daniel J. Hudock, PhD, CCC-SLP





5521 Ruffin Road
San Diego, CA 92123

e-mail: information@pluralpublishing.com
Website: <https://www.pluralpublishing.com>

Copyright © 2021 by Plural Publishing, Inc.

Typeset in 12/14 Adobe Garamond Pro by Flanagan's Publishing Services, Inc.
Printed in Canada by Friesens Corporation

All rights, including that of translation, reserved. No part of this publication may be reproduced, stored in a retrieval system, or transmitted in any form or by any means, electronic, mechanical, recording, or otherwise, including photocopying, recording, taping, Web distribution, or information storage and retrieval systems without the prior written consent of the publisher.

Photography by Sarah Moore, Susan Duncan, Eric Gordon, and Brian Smith.

For permission to use material from this text, contact us by
Telephone: (866) 758-7251
Fax: (888) 758-7255
e-mail: permissions@pluralpublishing.com

Every attempt has been made to contact the copyright holders for material originally printed in another source. If any have been inadvertently overlooked, the publisher will gladly make the necessary arrangements at the first opportunity.

Library of Congress Cataloging-in-Publication Data:

Names: Seikel, John A., author. | Drumright, David G., author. | Hudock, Daniel J., author.
Title: Anatomy & physiology for speech, language, and hearing / J. Anthony Seikel, David G. Drumright, Daniel J. Hudock.
Other titles: Anatomy and physiology for speech, language, and hearing
Description: Sixth edition. | San Diego, CA : Plural Publishing, [2020] | Includes bibliographical references and index.
Identifiers: LCCN 2019029690 | ISBN 9781635502794 (hardcover) | ISBN 1635502799 (hardcover) | ISBN 9781635503005 (ebook)
Subjects: MESH: Speech—physiology | Language | Hearing—physiology | Nervous System—anatomy & histology | Respiratory System—anatomy & histology | Respiratory Physiological Phenomena
Classification: LCC QP306 | NLM WV 501 | DDC 612.7/8—dc23
LC record available at <https://lcn.loc.gov/2019029690>

Contents

<i>Preface</i>	<i>xiii</i>
<i>About the Authors</i>	<i>xvii</i>
<i>About the Contributor</i>	<i>xix</i>
<i>Acknowledgments</i>	<i>xxi</i>
<i>Introduction to the Learner</i>	<i>xxiii</i>
<i>Using This Text</i>	<i>xxv</i>

Chapter 1 Basic Elements of Anatomy 1

Anatomy and Physiology	1
Terminology of Anatomy	3
Terms of Orientation	3
Terms of Movement	8
Parts of the Body	9
Building Blocks of Anatomy: Tissues and Systems	10
Tissues	11
Body Systems	27
Chapter Summary	39
Chapter 1 Study Questions	41
Chapter 1 Study Question Answers	44
Bibliography	46

Chapter 2 Anatomy of Respiration 47

The Support Structure of Respiration	50
Overview	50
Vertebral Column	51
Pelvic and Pectoral Girdles	60
Ribs and Rib Cage	66
Soft Tissue of the Thorax and Respiratory Passageway	71
Movement of Air Through the Respiratory System	88
Muscles of Inspiration	93
Muscles of Forced Expiration	120
Chapter Summary	132
Chapter 2 Study Questions	133
Chapter 2 Study Question Answers	140
Bibliography	142

Chapter 3	Physiology of Respiration	145
The Flow of Respiration		147
Instruments in Respiration		147
Respiration for Life		149
Effects of Turbulence on Respiration		149
Respiratory Cycle		150
Developmental Processes in Respiration		151
Lung Volumes and Capacities		152
Lung Volumes		153
Lung Capacities		156
Effect of Age on Volumes and Capacities		158
Pressures of the Respiratory System		160
Pressures Generated by the Tissue		166
Effects of Posture on Speech		169
Pressures and Volumes of Speech		171
Respiratory Pathologies Affecting Communication		177
Acute Conditions		177
Chronic Conditions		177
Neurogenic Etiologies		180
Chapter Summary		181
Chapter 3 Study Questions		182
Chapter 3 Study Question Answers		183
Bibliography		184

Chapter 4	Anatomy of Phonation	185
Framework of the Larynx		185
Inner Larynx		189
Laryngeal Membranes		190
Fine Structure of the Vocal Folds		196
Cavities of the Larynx		197
Cartilaginous Structure of the Larynx		203
Laryngeal Musculature		212
Intrinsic Laryngeal Muscles		213
Laryngeal Elevators and Depressors		225
Chapter Summary		239
Chapter 4 Study Questions		240
Chapter 4 Study Question Answers		244
Bibliography		245

Chapter 5	Physiology of Phonation	247
Nonspeech Laryngeal Function		247
Laryngeal Function for Speech		250
A Brief Discussion of Acoustics		251
Instruments for Voicing		256
The Bernoulli Effect		258
Vocal Attack		263
Termination		265
Sustained Phonation		267
Vocal Register		267
Frequency, Pitch, and Pitch Change		276
Intensity and Intensity Change		281
Clinical Considerations		285
Linguistic Aspects of Pitch and Intensity		287
Theories of Phonation		289
Pathologies That May Affect Phonation		290
Structural Etiologies		291
Degenerative Neurological Diseases		294
Chapter Summary		295
Decibel Practice Activity		296
Chapter 5 Study Questions		300
Chapter 5 Study Question Answers		301
Bibliography		301

Chapter 6	Anatomy of Articulation and Resonance	305
Source-Filter Theory of Vowel Production		305
The Articulators		309
Bones of the Face and Cranial Skeleton		321
Bones of the Face		321
Bones of the Cranial Skeleton		337
Dentition		346
Dental Development		352
Dental Occlusion		355
Cavities of the Articulatory System		359
Muscles of the Face and Mouth		366
Muscles of the Face		368
Muscles of the Mouth		376
Muscles of Mastication: Mandibular Elevators and Depressors		385

Muscles of the Velum	391
Muscles of the Pharynx	395
Chapter Summary	401
Chapter 6 Study Questions	404
Chapter 6 Study Question Answers	412
Bibliography	415

Chapter 7 Physiology of Articulation and Resonation 417

Instrumentation in Articulation	417
Speech Function	419
Lips	419
Mandible	421
Tongue	422
Velum	425
Development of Articulatory Ability	427
Coordinated Articulation	436
Central Control Theory	437
Dynamic or Action Theory Models	438
The DIVA Model of Speech Production	440
Pathologies That May Affect Articulation	444
Problems Affecting Dentition	445
Problems Affecting the Tongue	445
Mandibular and Maxillary Problems	446
Problems Affecting Lips and Palate	447
Neurogenic Conditions Affecting Speech	448
Chapter Summary	449
Chapter 7 Study Questions	450
Chapter 7 Study Question Answers	451
Bibliography	452

Chapter 8 Physiology of Mastication and Deglutition 455

Mastication and Deglutition	455
Instrumentation in Swallowing Function	456
Anatomical and Physiological Developmental Issues	457
Organizational Patterns of Mastication and Deglutition	460
Oral Stage: Oral Preparation	461
Oral Stage: Transport	464
Pharyngeal Stage	466

Esophageal Stage	472
Process Model of Mastication and Deglutition	473
Neurophysiological Underpinnings of Mastication and Deglutition	475
Sensation Associated with Mastication and Deglutition	475
Salivation Response	489
Reflexive Circuits of Mastication and Deglutition	491
Chewing Reflex	491
Orienting, Rooting, and Suckling/Sucking Reflexes	494
Uvular (Palatal) Reflex	494
Gag (Pharyngeal) Reflex	494
Retch and Vomit Reflex	495
Cough Reflex	495
Pain Withdrawal Reflex	495
Apneic Reflex	496
Respiration Reflexes	496
Swallowing Reflex	496
Reexamination of the Patterns for Mastication and Deglutition:	498
A Complex Integration of Reflexes and Voluntary Action	
Pathologies Affecting Swallowing Function	500
Chapter Summary	503
Chapter 8 Study Questions	505
Chapter 8 Study Question Answers	508
Bibliography	510

Chapter 9 Anatomy of Hearing 515

The Structures of Hearing	515
Outer Ear	516
Middle Ear	520
Structure of the Tympanic Membrane	520
Landmarks of the Middle Ear	528
Inner Ear	530
Osseous Vestibule	530
Osseous Semicircular Canals	534
Osseous Cochlear Labyrinth	534
Innervation Pattern of the Organ of Corti	540
Chapter Summary	543
Chapter 9 Study Questions	544
Chapter 9 Study Question Answers	546
Bibliography	547

Chapter 10 Auditory Physiology 549

Instrumentation in Hearing Research	549
Outer Ear	550
Middle Ear Function	552
Inner Ear Function	553
Vestibular Mechanism	553
Auditory Mechanism: Mechanical Events	555
Electrical Events	560
Resting Potentials	562
Potentials Arising from Stimulation	562
Neural Responses	564
Post-Stimulus Time Histograms	565
Interspike Interval and Period Histograms	569
Frequency Selectivity	570
Auditory Pathway Responses	573
Pathologies That May Affect Audition	589
Inflammatory Conditions	589
Congenital Problems	590
Traumatic Lesions	590
Neoplastic Changes	590
Bone Changes	591
Semicircular Canal Dehiscence	591
Chapter Summary	592
Chapter 10 Study Questions	594
Chapter 10 Study Question Answers	596
Bibliography	597

Chapter 11 Neuroanatomy 601

Overview	601
Divisions of the Nervous System	607
Central Nervous System and Peripheral Nervous System	608
Autonomic and Somatic Nervous Systems	608
Development Divisions	610
Anatomy of the CNS and PNS	610
Neurons	612
Anatomy of the Cerebrum	621
Medial Surface of Cerebral Cortex	652
Inferior Surface of Cerebral Cortex	652
Myelinated Fibers	653

Anatomy of the Subcortex	655
Cerebrovascular System	663
Cerebellum	667
Anatomy of the Brain Stem	673
Superficial Brain Stem Landmarks	673
Deep Structure of the Brain Stem	679
Cranial Nerves	686
Cranial Nerve Classification	686
Specific Cranial Nerves	689
Anatomy of the Spinal Cord	711
Chapter Summary	731
Chapter 11 Study Questions	733
Chapter 11 Study Question Answers	739
Bibliography	741

Chapter 12 Neurophysiology 745

Instrumentation in Neurophysiology	745
The Neuron	748
Neuron Function	748
Muscle Function	758
Higher Functioning	769
Motor System Lesions	774
Afferent Inputs	777
Association Regions	778
Hemispheric Specialization	781
Lesion Studies	782
Motor Control for Speech	791
Neurogenic Conditions That May Affect Communication	794
Acquired Conditions	794
Progressive Degenerative Diseases	795
Chapter Summary	799
Chapter 12 Study Questions	801
Chapter 12 Study Question Answers	803
Bibliography	804

Appendix A Anatomical Terms 807

Appendix B Useful Combining Forms 809

Appendix C Muscles of Respiration 813

Thoracic Muscles of Inspiration	813
Primary Inspiratory Muscle	813
Accessory Thoracic Muscles of Inspiration	813
Erector Spinae (Sacrospinal Muscles)	814
Accessory Muscles of Neck	816
Muscles of Upper Arm and Shoulder	817
Thoracic Muscles of Expiration	818
Posterior Thoracic Muscles	819
Abdominal Muscles of Expiration	819
Anterolateral Abdominal Muscles	819
Posterior Abdominal Muscles	820
Muscles of Upper Limb	820

Appendix D Muscles of Phonation 821

Intrinsic Laryngeal Muscles	821
Extrinsic Laryngeal, Infrahyoid, and Suprahyoid Muscles	823
Hyoid and Laryngeal Elevators	823
Hyoid and Laryngeal Depressors	824

Appendix E Muscles of Face, Soft Palate, and Pharynx 825

Muscles of the Face	825
Intrinsic Tongue Muscles	827
Extrinsic Tongue Muscles	828
Mandibular Elevators and Depressors	829
Muscles of the Velum	830
Muscles of the Pharynx	831

Appendix F Sensors 833

General Classes	833
Specific Types	833
Classes of Sensation	833

Appendix G Cranial Nerves 835

Classes of Cranial Nerves	835
Cranial Nerves and Sources	835

<i>Glossary</i>	839
<i>Index</i>	889

Preface

A*natomy & Physiology for Speech, Language, and Hearing, Sixth Edition*, provides a sequential tour of the anatomy and physiology associated with speech, language, and hearing. We aspire to keep the content alive for students of today by providing not only basic anatomy and physiology, but also by forging the relationship between the structures and functions and the dysfunction that occurs when the systems fail. We know that students in audiology and speech-language pathology have their future clients in mind as they read this content, and we hope that by integrating information about pathology we can bring anatomy to life and to relevancy for you.

We have designed this text and the support materials to serve the upper division undergraduate or graduate student in the fields of speech-language pathology and audiology, and hope that it can serve you as a reference for your professional life as well. We aspire for it to be a learning tool and resource for both the developing and the accomplished clinician. We, the authors of this text, are first and foremost teachers ourselves. We are committed to the students within our professions and to the instructors who have made it their life work to teach them. Learning is a lifelong process, and our goal is to give instructors the tools to start students on that lifelong professional path and to inspire learning throughout your life. We know that learning is not a spectator sport because we continue to engage ourselves as learners. Our goal is to make the text and its ancillary materials as useful to 21st-century students as possible. This new edition not only provides students with great interactive study tools in the revised and renamed ANAQUEST study software, but also makes available a wealth of student and instructor resources to facilitate learning. We want you to be the best clinician and scientist you can be and sincerely hope that these materials move you along the path of your chosen career.

Organization

The text is organized around the five “classic” systems of speech and hearing: the respiratory, phonatory, articulatory/resonatory, nervous, and auditory systems. The respiratory system (involving the lungs) provides the “energy source” for speech, whereas the phonatory system (involving the larynx) provides voicing. The articulatory/resonatory system modifies the acoustic source provided by voicing (or other gestures) to produce the sounds we acknowledge as speech. The articulatory system is responsible for the mastication (chewing) and deglutition (swallowing) function, an increasingly important area within the field of speech-language pathology. The nervous system lets us control musculature, receive information, and make sense

of the information. Finally, the auditory mechanism processes speech and nonspeech acoustic signals received by the listener who is trying to make sense of her or his world.

There are few areas of study where the potential for overwhelming detail is greater than in the disciplines of anatomy and physiology. Our desire with this text and the accompanying software lessons is to provide a stable foundation upon which detail may be learned. In the text, we provide you with an introductory section that sets the stage for the detail to follow, and we bring you back to a more global picture with summaries. We have also provided derivations of words to help you remember technical terms.

New to the Sixth Edition

This new edition of *Anatomy & Physiology for Speech, Language, and Hearing, Sixth Edition* includes many exciting enhancements:

- Revised and updated physiology of swallowing includes discussion of orofacial-myofunctional disorders and other swallowing dysfunction arising from physical etiologies.
- An introduction to the effects of pathology on communication is included within each of the physical systems of communication.
- Many new photographs of specimens have been added, with a focus on a clear and accurate understanding of the classical framework of the speech, language, and hearing systems.
- *Clinical Notes* boxes link anatomy and physiology with disorders seen by speech-language pathologists and audiologists to provide real-world applications for students.
- The ANAQUEST study software is Internet-based and accessible on the PluralPlus companion website that comes with the text. ANAQUEST provides on-the-go learning, with animation lessons, simulations, and updates to content. The software now includes a set of video lab experiences narrated by new contributor Katrina Rhett, an anatomist and lecturer in the Department of Biological Sciences at Idaho State University. We have added three-dimensional views with animations that explore the important processes of hearing, phonation, respiration, swallowing, and more.

See the beginning of the textbook for instructions on how to access the PluralPlus companion website.

The PluralPlus companion website is divided into two areas: one housing materials for the instructor and the other just for students.

For the Instructor

The PluralPlus companion website contains a variety of tools to help instructors successfully prepare lectures and teach within this subject area. This comprehensive package provides something for all instructors, from those

teaching anatomy and physiology for the first time to seasoned instructors who want something new. The following materials have been made available just for instructors:

- An *Instructor's Manual* containing materials and suggested activities for the lecture and lab guides to facilitate learning outside of the classroom.
- A *test bank* with approximately 1,000 questions and answers, for use in instructor-created quizzes and tests.
- *PowerPoint lecture slides* for each chapter to use as in-class lecture material and as handouts for students.
- A version of the ANAQUEST study software created for upload to a Learning Management System (LMS).

For the Student

ANAQUEST study software comes with purchase of the textbook and can be accessed on the PluralPlus companion website. ANAQUEST software is your true partner in learning. The available labs give you the opportunity to examine structures and functions of the speech mechanism in an interactive digital environment. The ANAQUEST software is keyed to the text, reinforcing identification of the structures presented during lecture, but more importantly illustrating the function of those structures. An icon in the margin of the text indicates that you'll find related lessons and video labs in ANAQUEST, where you can examine speech physiology through the interactive manipulation of the structures under study, and learn the relationship of the body parts and how they function together. See the beginning of the textbook for the website URL and your access code.

*J. Anthony Seikel
David G. Drumright
Daniel J. Hudock*

About the Authors

J. Anthony (Tony) Seikel, PhD, is emeritus faculty at Idaho State University, where he taught graduate and undergraduate coursework in neuroanatomy and neuropathology over the course of his career in Communication Sciences and Disorders. He is coauthor of numerous chapters, books, and research publications in the fields of speech-language pathology and audiology. His current research is examining the relationship between orofacial myofunctional disorders and oropharyngeal dysphagia. Dr. Seikel is also coauthor of *Neuroanatomy & Neurophysiology for Speech and Hearing Sciences*, also published by Plural Publishing in 2018.

David G. Drumright, BS, grew up in Oklahoma and Kansas, taught electronics at DeVry for several years, then spent 20 years as a technician in acoustics and speech research. He developed many programs and devices for analysis and instruction in acoustics and speech/hearing. He has been semiretired since 2002, working on graphics and programming for courseware. He is also coauthor of *Neuroanatomy & Neurophysiology for Speech and Hearing Sciences*, published by Plural Publishing in 2018.

Daniel J. Hudock, PhD, CCC-SLP, is an Associate Professor of Communication Sciences and Disorders at Idaho State University who has taught courses on Anatomy & Physiology of the Speech and Hearing Mechanisms and Speech & Hearing Science for over a decade. He has published more than 30 articles and has given over 100 presentations. In his TEDx Talk (<https://bit.ly/2oAYeKC>) entitled “Please Let Me Finish My Sentence,” he presents about his experience living with a stutter. Dr. Hudock is also the founding director of the Northwest Center for Fluency Disorders that offers an intensive interprofessional stuttering clinic with speech language pathologists collaborating with counselors and clinical psychologists through an Acceptance and Commitment Therapy (ACT) informed framework in the treatment of adolescent and adult stuttering, which is his main area of research.

About the Contributor

Katrina Rhett, MS, is an Assistant Lecturer in the Department of Biological Sciences at Idaho State University where she administers dissection-based and prosection-based human gross anatomy courses. She teaches undergraduate anatomy and physiology lab, graduate anatomy lab for the physical and occupational therapy programs, and advanced medical workshops. Prior to joining the faculty at Idaho State University, she taught undergraduate and medical human gross anatomy courses and conducted research in cardiovascular and muscular research labs at the University of Minnesota.

Acknowledgments

We are deeply indebted to our friends at Plural Publishing who have worked so hard to make this new edition happen. Frankly, we feel that we have returned home after a long time away, because this text began as a “twinkle in the eye” of Dr. Sadanand Singh, then owner of Singular Publishing. We were affiliated with another publisher for many years after, but are excited and relieved to have returned to our home in Plural Publishing, and to the capable and compassionate hands of Angie Singh and Valerie Johns. Angie and Val have had the vision to see this text through to its sixth edition, and we are forever grateful for their support and determination.

We would like to acknowledge the effort that reviewers put into their examination of our material and hope we have done justice to their work. Reviewers are the unsung heroes of textbook preparation. They put in long and often tedious hours, examining our work with an unflinching eye. The deadlines that they faced in reviewing the material for this sixth edition were daunting, and yet they persevered. We are very deeply indebted to them for their careful review and willingness to call our attention to areas that need refinement and improvement. We also are grateful for their keen insight and discernment, and hope that we have in some measure answered their suggestions. This textbook is written, quite literally, on their shoulders.

We also wish to acknowledge all those who have, over the course of the past few years, given us corrections and suggestions for improving the text. Patrick Walden, Mayrose McInerney, Nelson Roy, and Shawn Nissen have provided inspiration to us through their love of teaching. It has been inspiring to be once again in communication with Tanis Tranka and Lyn Russell. There are many other instructors and students with whom we have had the fortune to work and who have provided valuable feedback on the text, and we appreciate every one of you.

To you, our students, please realize that your future clients support your present intention and also will serve as your inspiration as you move through life. As speech-language pathologists and audiologists, we must acknowledge the tremendous debt we owe to the great researchers and teachers who have formed the profession, our colleagues with whom we consult and work, and, always, our clients, who have taught us more than any textbook could.

As authors, we must also acknowledge the source of our inspiration. We have been actively involved in teaching students in speech-language pathology and audiology for some time, and not a semester goes by that we don't realize how very dedicated our students are. There is something special about our field that attracts not just the brightest, but the most compassionate. You, students, keep us as teachers alive and vital. Thank you.

Introduction to the Learner

We continue to be impressed with the complexity and beauty of the systems of human communication. Humans use an extremely complex system for communication, requiring extraordinary coordination and control of an intensely interconnected sensorimotor system. It is our heartfelt desire that the study of the physical system will lead you to an appreciation of the importance of your future work as a speech-language pathologist or audiologist.

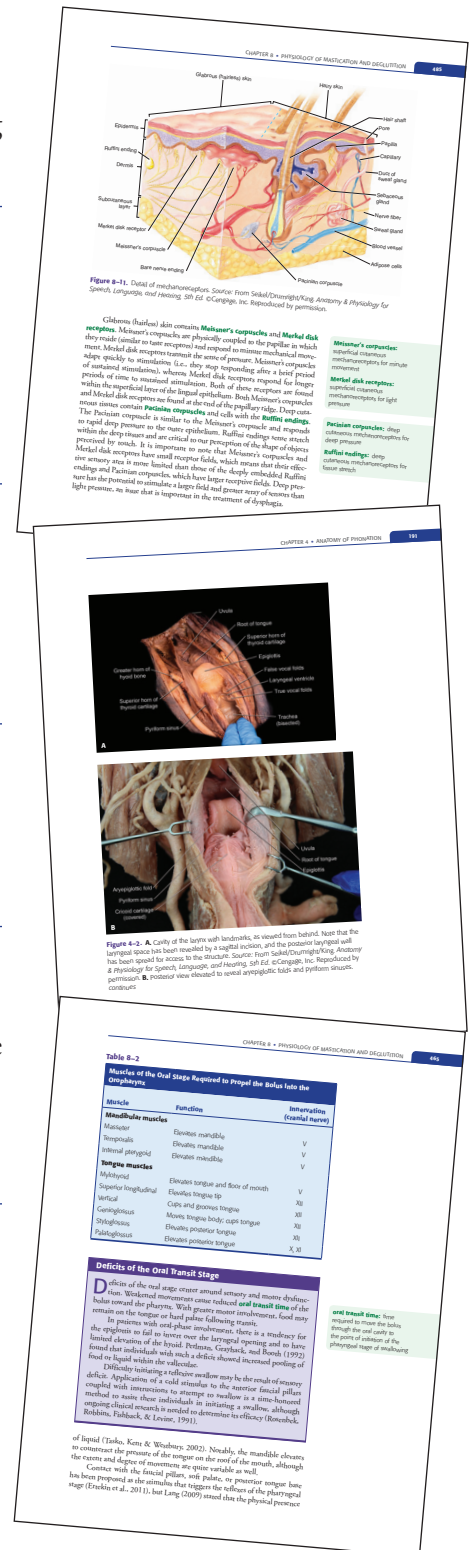
We also know that the intensity of your study will work to the benefit of your future clients and that the knowledge you gain through your effort will be applied throughout your career. We appreciate the fact that the study of anatomy is challenging, but we also recognize that the effort you put forth now will provide you with the background for work with the medical community.

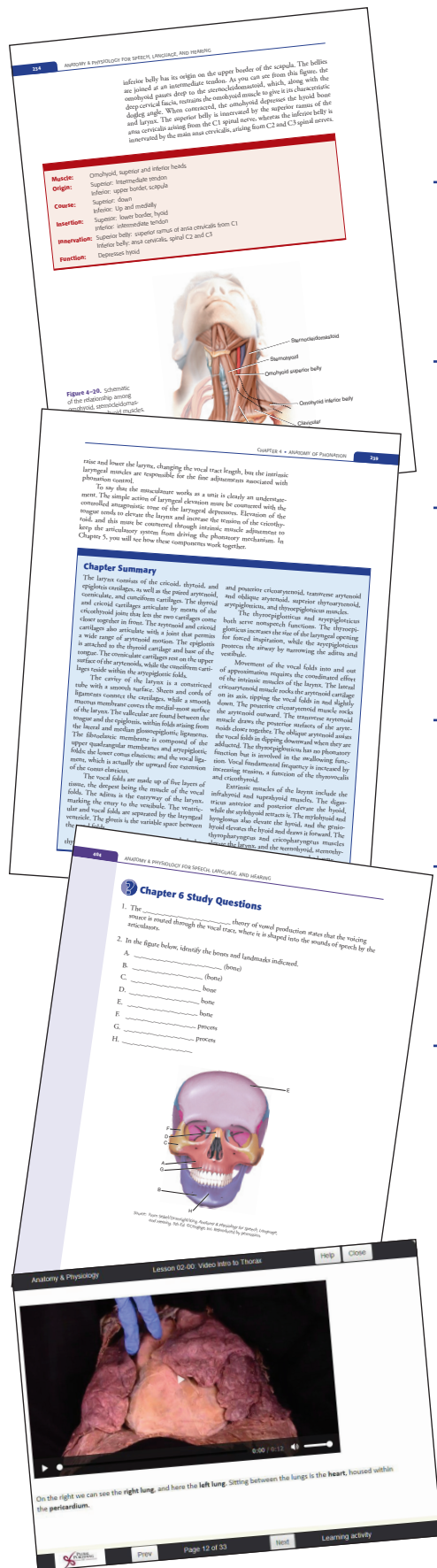A deep understanding of the structure and function of the human body is critical to the individual who is charged with the diagnosis and treatment of speech, language, and hearing disorders. As beginning clinicians, you are already aware of the awesome responsibility you bear in clinical management. It is our firm belief that knowledge of the human body and how it works will provide you with the background you need to make informed and wise decisions. We welcome you on your journey into the world of anatomy.

Using This Text

Use the elements found in the text to help guide you as you move along the path of your chosen career. The text offers the following features:

- Margin Notes** identify important terminology, root words, and definitions, which are highlighted in color throughout each chapter. Other important terms are boldfaced in text to indicate that a corresponding definition can be found in the Glossary at the end of the book. Use these terms to study and prepare for tests and quizzes.
- Clinical Notes** relate a topic directly to clinical experience to emphasize the importance of anatomy in your clinical practice. Gain insight into your chosen profession by using the topics discussed for research papers, to facilitate in-class discussion, and to complete homework assignments.
- Photographs** provide a real-life look at the body parts and functions you are studying. Use these images as reference for accuracy in describing body systems, parts, and processes. Allow yourself to be amazed by the intricacies of human anatomy!
- Illustrations and Graphs** provide visual examples of the anatomy, processes, and body systems discussed. Refer to the figures as you read the text to enhance your understanding of the specific idea or anatomical component being discussed. When reviewing for quizzes and tests, refer back to the figures for an important visual recap of the topics discussed.
- Tables** highlight the various components, functions, structures, and pathologies of anatomical concepts related to what you might encounter in actual practice. Use these tables for quick reference to study and learn to relate your new anatomical knowledge to clinical experience.





- **“To Summarize” sections** provide a succinct listing of the major topics covered in a chapter or chapter section. These summaries provide a helpful recap of the general areas where you should focus your time while reviewing for examinations.
- **Muscle Tables** describe the origin, course, insertion, innervation, and function of key muscles and muscle groups. Use these tables to stay organized and keep track of the numerous muscles studied in each chapter.
- **Chapter Summaries** provide precise reviews of content. The summary is offset from the running text to make it easily identifiable for quick review.
- **Study Questions and Answers** can be completed after reading a chapter to help you identify areas you may need to reread or focus on while studying. Complete the questions again as you review for a midterm or final examination to help keep the content fresh in your memory.
- A **Bibliography** with a comprehensive list of references at the end of each chapter offers great sources to start your research for a paper or class project.
- **Appendices** include an alphabetical listing of anatomical terms, useful combining forms, and listings of sensors and cranial nerves. You will also find a complete **Glossary** of all key terms found throughout the text.
- The **ANAQUEST** software labs and videos are self-paced, with frequent quizzes to help you examine the effectiveness of your study habits. If you spend two or three half-hour sessions per week with the ANAQUEST software, you will get the greatest benefit from your classes and readings. The software will also prove a great refresher in preparing for quizzes and examinations.

The authors wish to dedicate this text to the many clients we have known over our years of practice who have inspired us with their courage and wisdom. We also wish to dedicate this text to the students and faculty in speech and hearing who do the work of helping people with communication and swallowing difficulties. We have been blessed with our associations with you for many decades, and we know that audiologists and speech-language pathologists are compassionate and generous people who dedicate their lives to improving the well-being of others in what we, the authors, consider the most important aspect of life: communication. We thank you, the faculty and students of our fields, for your dedication.

—*JAS, DGD, and DJH*

I also dedicate the text to my four research mentors. Robert McCroskey, my first research mentor, would exclaim “data!” when he saw a printout, gleeful that he could pry some more meaning from observations. John Brandt gave me an “Occam’s razor” with which to discern signal from noise, figure from ground. John Ferraro gave me a love of electrophysiological processes (as well as loan of his electrophysiological lab facility!) that has inspired my love of the hearing mechanism throughout my career. Kim Wilcox blessed me with passion for research and a sense of humor that has sustained me throughout my career. To all of these giants, I say “thank you” for the gift.

—*Tony Seikel*

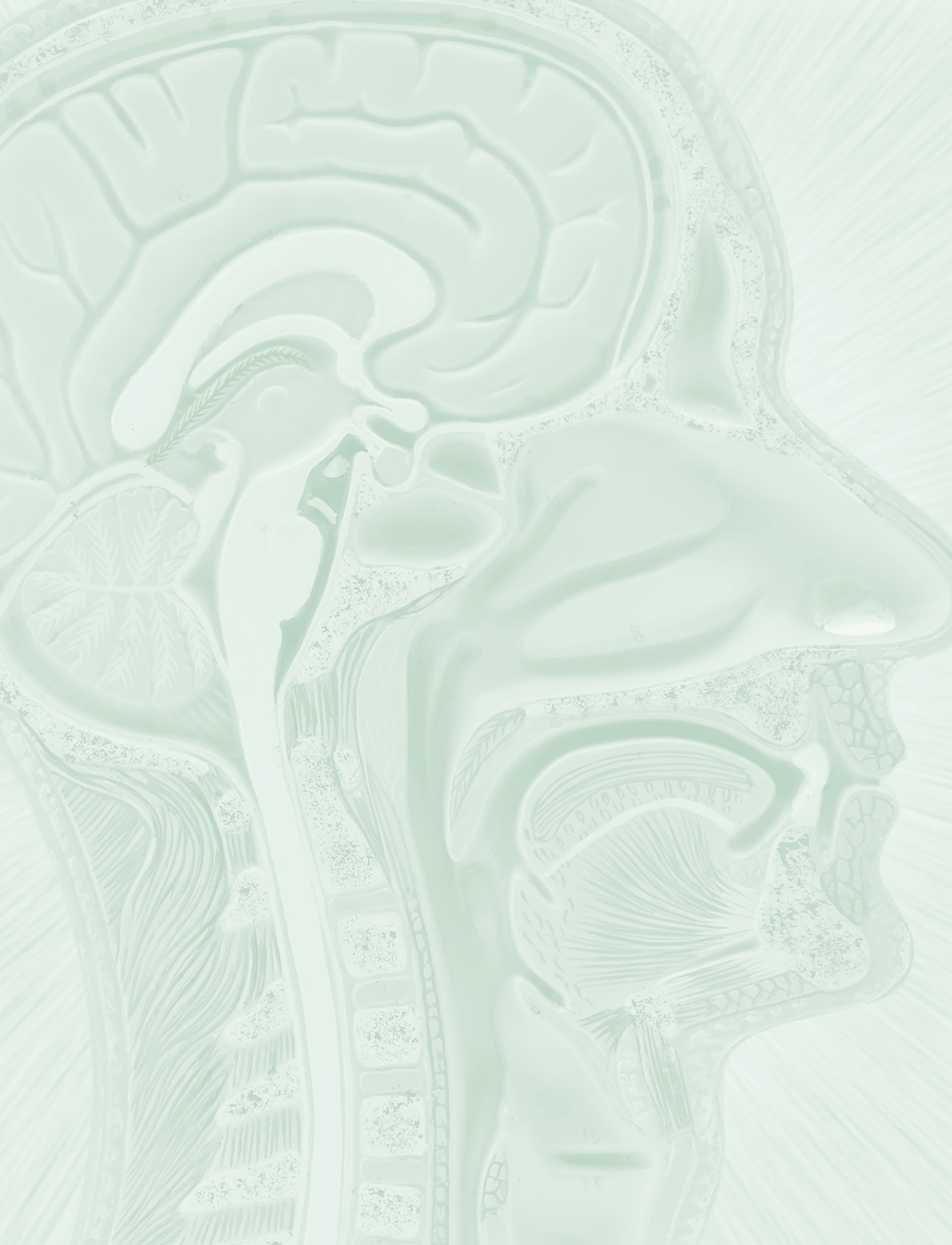
I also dedicate the accompanying software to Professor Merle Phillips, who taught me something about audiology and a lot about life.

—*David Drumright*

I wish to dedicate my contributions to the text to the first author, “Tony,” who has been a beloved colleague, mentor, and dear friend over the past several years. Tony’s passion for the field, colleagues, teaching, and students knows no bounds as he has tirelessly and compassionately given of himself for the betterment of others.

I would also like to dedicate my contributions to this book to the many speech-language pathologists, teachers, professors, students, friends, and family that have supported him along the way. There are no words that can fully express my gratitude and appreciation for the kindness and support shown to me. Thank you.

—*Dan Hudock*



Basic Elements of Anatomy

You are entering into study of the human body that has a long and rich tradition. We are fortunate to have myriad instruments and techniques at our avail for this study, but it has not always been so. You will likely struggle with arcane terminology that seems confusing and strange, and yet if you look closely, you will see what the early anatomists first saw. The amygdala of the brain is a small almond-shaped structure, and *amygdala* means almond. *Lentiform* literally means lens-shaped, and the lentiform nucleus is just that. The fact that the terminology remains in our lexicon indicates the accuracy with which our academic ancestors studied their field, despite extraordinarily limited resources.

This chapter provides you with some basic elements to prepare you for your study of the anatomy and physiology of speech, language, and hearing. We provide a broad picture of the field of anatomy and then introduce you to the basic tissues that make up the human body. Tissues combine to form structures, and those structures combine to form systems. This chapter sets the stage for your understanding of the new and foreign anatomical terminologies.

Anatomy and Physiology

Anatomy refers to the study of the *structure* of an organism. **Physiology** is the study of the *function* of the living organism and its parts, as well as the chemical processes involved. **Applied anatomy** (also known as **clinical anatomy**) involves the application of anatomical study for the diagnosis and treatment of disease and surgical procedures. **Descriptive anatomy** (also known as **systemic anatomy**) is description of individual parts of the body without reference to disease conditions, viewing the body as a composite of systems that function together.

Gross anatomy studies structures that are visible without a microscope, while **microscopic anatomy** examines structures not visible to the unaided eye. **Surface anatomy** (also known as **superficial anatomy**) studies the form and structure of the surface of the body, especially with reference to the organs beneath the surface (Agur & Dalley, 2012; Gilroy, MacPherson, & Ross, 2012; Rohen, Lutjen-Drecoll, & Yokochi, 2010; Standring, 2008).

ANAQUEST LESSON

anatomy: Gr., anatome, **dissection**

dissection: L., dissecare, the process of cutting up

physiology: Gr., physis, nature; and logos, study; function of an organism

applied anatomy or **clinical anatomy:** application of anatomical study for the diagnosis and treatment of disease, particularly as it relates to surgical procedures

descriptive anatomy or **systemic anatomy:** anatomical specialty involving the description of individual parts of the body without reference to disease conditions

gross anatomy: study of the body and its parts as visible without the aid of microscopy

microscopic anatomy: study of the structure of the body by means of microscopy

surface anatomy or **superficial anatomy:** study of the body and its surface markings as related to underlying structures

developmental anatomy:

study of anatomy with reference to growth and development from conception to adulthood

pathological anatomy: study of parts of the body with respect to the pathological entity

comparative anatomy: study of homologous structures of different animals

electrophysiological

techniques: those techniques that measure the electrical activity of single cells or groups of cells, including muscle and nervous system tissues

cytology: Gr., kytos, cell; logos, study

histology: Gr., histos, web, tissue; logos, study

osteology: Gr., osteon, bone; logos, study

myology: Gr., mys, muscle; logos, study

arthrology: Gr., arthron, joint; logos, study

angiology: Gr., angio, blood vessels; logos, study

neurology: Gr., neuron, sinew, nerve; logos, study

Developmental anatomy deals with the development of the organism from conception (Moore, Persaud, & Torchia, 2013).

When your study examines disease conditions or structural abnormalities, you have entered the domain of **pathological anatomy**. When we make comparisons across species boundaries, we are engaged in **comparative anatomy**.

Examination of physiological processes may entail the use of a range of methods, from simply measuring forces exerted by muscles, to highly refined **electrophysiological techniques** that measure electrical activity of single cells or groups of cells, including muscle and nervous system tissues. For example, audiologists are particularly interested in procedures that measure the electrical activity of the brain caused by auditory stimuli (**evoked auditory potentials**). We rely heavily on descriptive anatomy to guide our understanding of the physical mechanisms of speech and to aid our discussion of its physiology (e.g., Duffy, 2012). Study of pathological anatomy occurs naturally as you enter your clinical process, because many of the acquired conditions speech-language pathologists or audiologists work with arise from pathological changes in structure.

We will need to call on knowledge from related fields to support your study of anatomy and physiology. **Cytology** is the discipline that examines structure and function of cells; **histology** is the microscopic study of cells and tissues. **Osteology** studies structure and function of bones, while **myology** examines muscle form and function. **Arthrology** studies the joints uniting bones, and **angiology** is the study of blood vessels and the lymphatic system. **Neurology** is the study of diseases of the nervous system.

Teratogens

A **teratogen** or teratogenic agent is anything causing teratogenesis, the development of a severely malformed fetus. For an agent to be teratogenic, its effect must occur during prenatal development.

Because the development of the fetus involves the proliferation and differentiation of tissues, the timing of the teratogen is particularly critical. The heart undergoes its most critical period of development from the third embryonic week to the eighth, while the critical period for the palate begins around the fifth week and ends around the 12th week. The critical period for neural development stretches from the third embryonic week

until birth. These critical periods for development mark the points at which the developing human is most susceptible to insult. An agent destined to have an effect on the development of an organ or system will have its greatest impact during that critical period.

Many teratogens have been identified, including organic mercury (which causes cerebral palsy, mental retardation, blindness, cerebral atrophy, and seizures), heroin and morphine (causing neonatal convulsions, tremors, and death), alcohol (fetal alcohol syndrome, mental retardation, microcephaly, joint anomalies, and maxillary anomalies), and tobacco (growth retardation), to name just a few.

✓ To summarize:

- **Anatomy** is the study of the structure of an organism; **physiology** is the study of function.
- **Descriptive anatomy** relates the individual parts of the body to functional systems.
- **Pathological anatomy** refers to changes in structure as they relate to disease.
- **Gross** and **microscopic anatomy** refer to levels of visibility of structures under study.
- **Developmental anatomy** examines growth and development of an organism.
- **Cytology** and **histology** study cells and tissues, respectively. **Myology** examines muscle form and function.
- **Arthrology** refers to the study of the joint system for bones, while **osteology** is the study of form and function of bones.
- **Neurology** refers to the study of diseases of the nervous system.

Terminology of Anatomy

Terminology allows us to communicate relevant information concerning the location and orientation of various body parts and organs, so clarity of terminology is of the utmost importance in the study of anatomy. Terminology also links us to the historic roots of this field of study. To the budding scholar of Latin or Greek, learning the terms of anatomy is an exciting reminder of our linguistic history. To the rest of us, the terms we are about to discuss may be less easily digested but are nonetheless important.

As you prepare for your study of anatomy, please realize that this body of knowledge is extremely hierarchical. *What you learn today will be the basis for what you learn tomorrow.* Not only are the terms the bedrock for understanding anatomical structures, but also mastery of their usage will let you gain the maximum benefit from new material presented.

Terms of Orientation

In the **anatomical position**, the body is erect, and the palms, arms, and hands face forward, as shown in Figure 1–1A. Terms of direction assume this position. The body and brain (and many other structures) are seen to have axes (plural of axis) or midlines from which other structures arise. The **axial skeleton** is the head and trunk, with the spinal column being the axis, while the **appendicular skeleton** includes the upper and lower limbs. The **neuraxis**, or the axis of the brain, is slightly less straightforward due to morphological changes of the brain during development. The embryonic nervous system is essentially tubular, but as the cerebral cortex develops, a

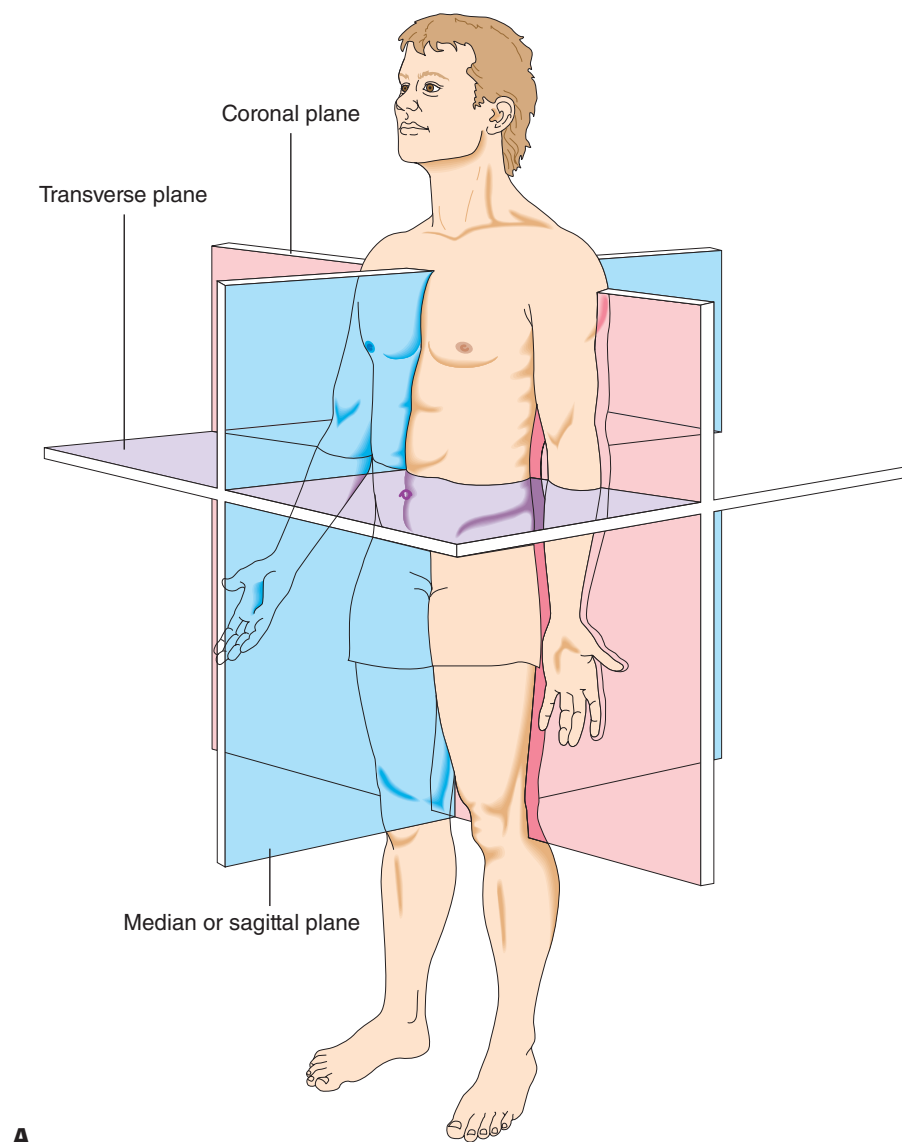
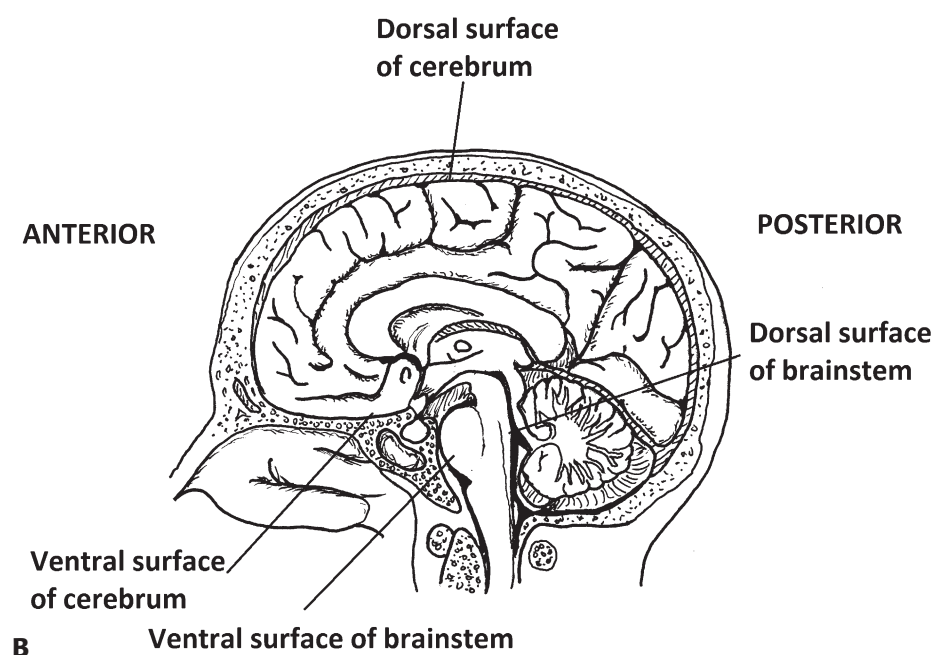


Figure 1-1. A. Terms and planes of orientation. *Source:* From Seikel/Drumright/King. *Anatomy & Physiology for Speech, Language, and Hearing, 5th Ed.* ©Cengage, Inc. Reproduced by permission.

B. The neuraxis of the brain. *Source:* From *Neuroanatomy & Neurophysiology for Speech, Language and Hearing* by Seikel, J. A., Konstantopoulos, K. & Drumright, D. G. Copyright © 2020 Plural Publishing, Inc. *continues*



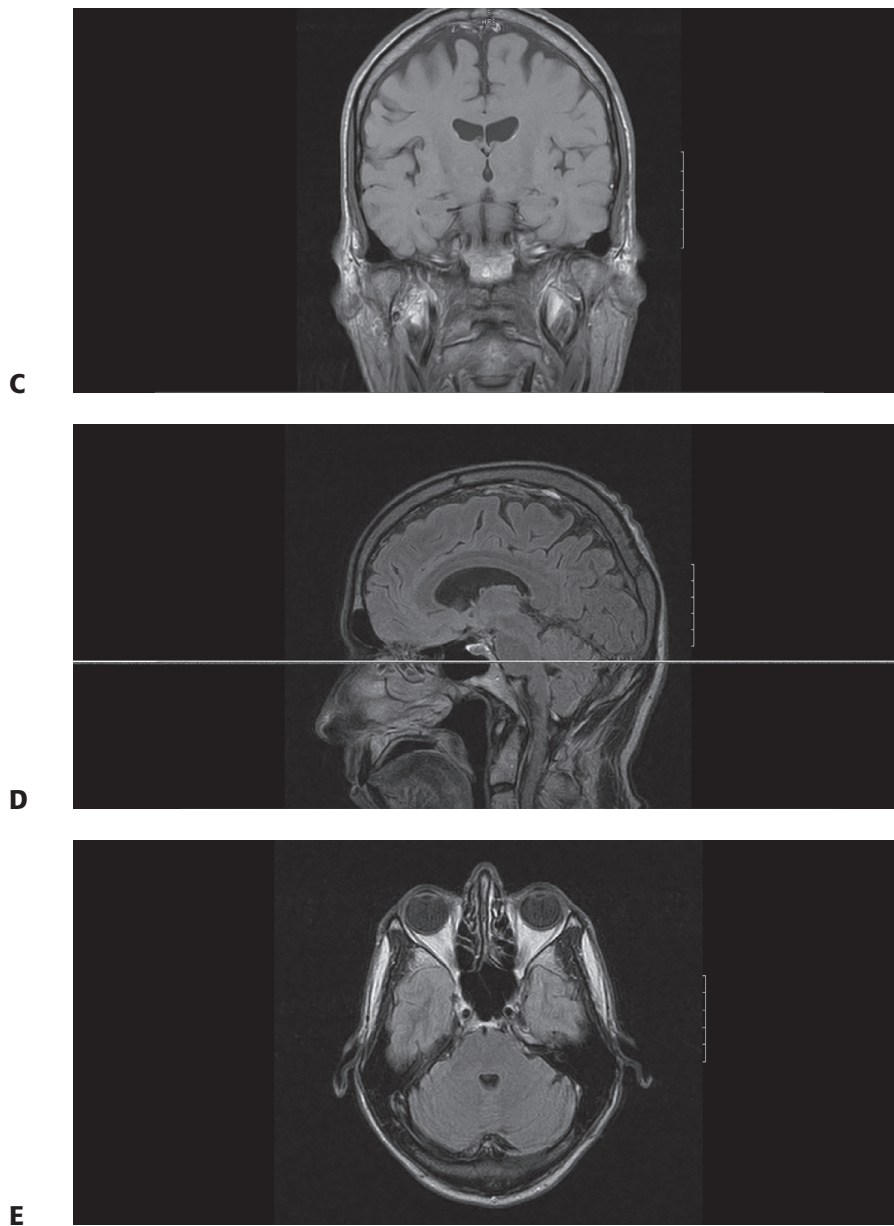


Figure 1-1. *continued*

C. Coronal section through the brain and skull using magnetic resonance imaging (MRI). **D.** Sagittal or median section through the brain and skull using MRI. **E.** Transverse section through the brain and skull using MRI. *Source:* From Seikel/Drumright/King. *Anatomy & Physiology for Speech, Language, and Hearing, 5th Ed.* ©Cengage, Inc. Reproduced by permission. *continues*

flexure occurs and the telencephalon (the region that will become the cerebrum) folds forward. As a result, the neuraxis assumes a T-formation (Moore et al., 2013). The spinal cord and brain stem have dorsal (back) and ventral (front) surfaces corresponding to those of the surface of the body. Because the cerebrum folds forward, the dorsal surface is also the superior surface, and the ventral surface is the inferior surface. Most anatomists avoid this confusing state by referring to the ventral and dorsal surfaces of the embryonic brain as inferior and superior surfaces, respectively (Figure 1-1G).

Some terms are related to the physical orientation of the body (such as *vertical* or *horizontal*). Other terms (such as *frontal*, *coronal*, and *longitudinal*) refer to planes or axes of the body and are therefore insensitive to the position of the body.

Those of you who play cards may remember “ante up,” meaning “put your money up front!” You may remember the term antebellum, meaning “before the war.”

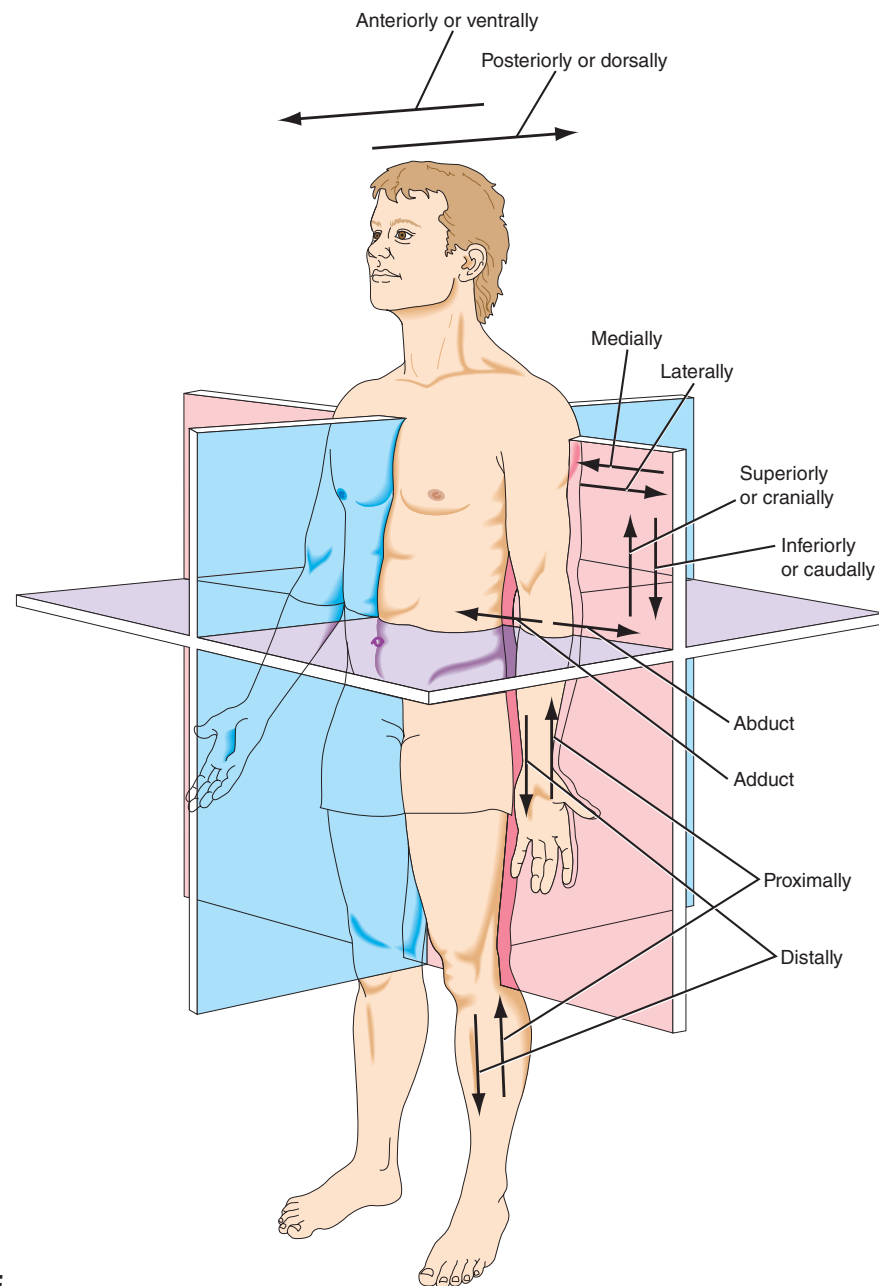


Figure 1–1. *continued*

F. Terms of movement. Source: From Seikel/Drumright/King. *Anatomy & Physiology for Speech, Language, and Hearing, 5th Ed.* ©Cengage, Inc. Reproduced by permission. *continues*

F

frontal section or frontal view: divides body into front and back halves

midsagittal section: an anatomical section that divides the body into left and right halves in the median plane

sagittal section: divides the body or body part into right and left halves

You may think of the following planes as referring to sections of a standing body, but they are actually defined relative to imaginary axes of the body. If you were to divide the body into front and back sections, you would have produced a **frontal section** or **frontal view**. If you cut the body into left and right halves, this would be along the median plane and it would produce **midsagittal sections**. A **sagittal section** is any cut that is parallel to the median plane and divides the body into left and right portions: The cut is in the sagittal plane. The **transverse plane** divides the body into upper and lower portions (this plane is often referred to by radiologists as *transaxial* or *axial*, and the radiological orientation always assumes you are looking from the feet toward the head). Figure 1–1A illustrates these sections. Armed with

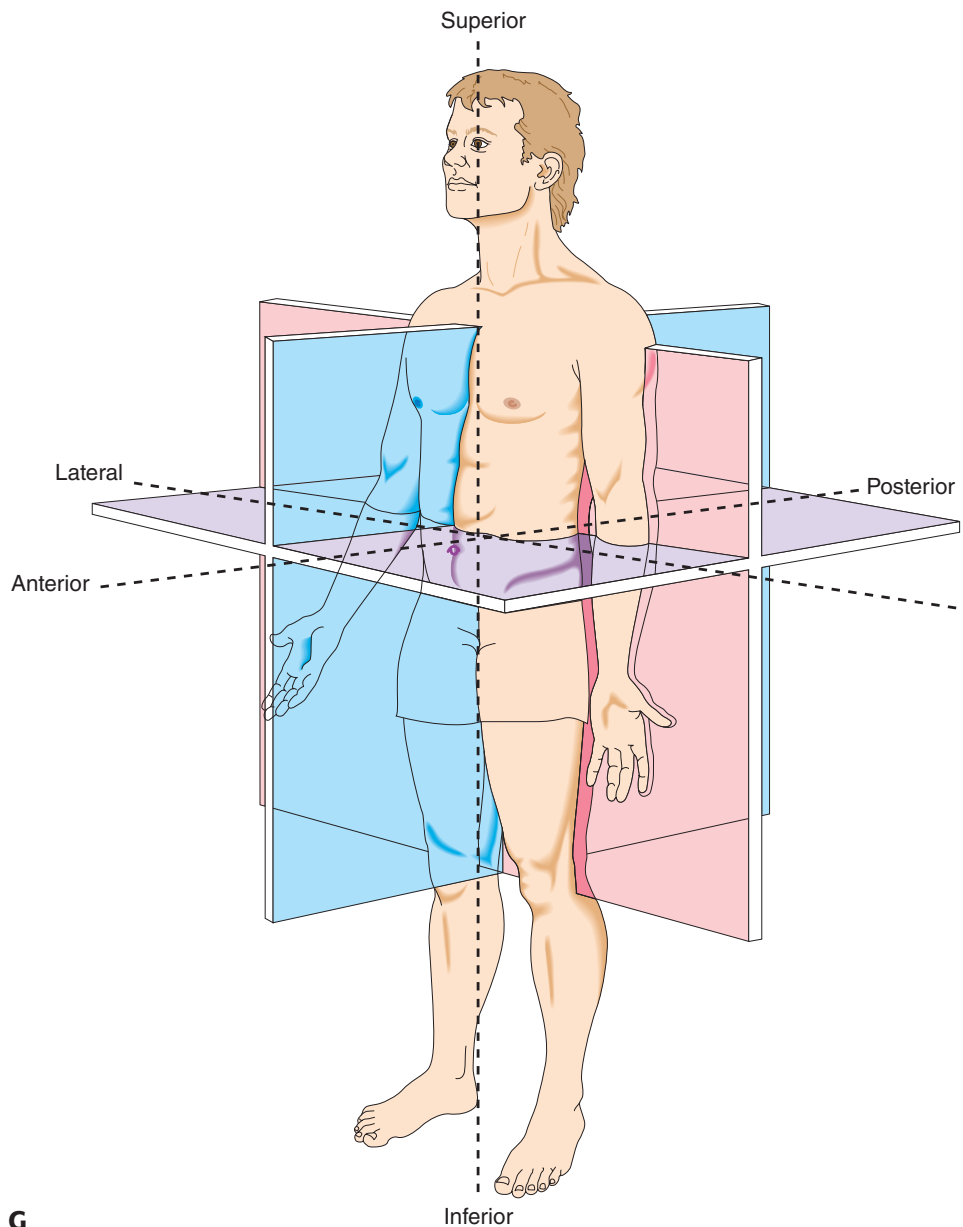


Figure 1–1. *continued*

G. Terms of spatial orientation. Source: From Seikel/Drumright/King. *Anatomy & Physiology for Speech, Language, and Hearing*, 5th Ed. ©Cengage, Inc. Reproduced by permission.

these basic planes of reference, you could rotate a structure in space and still discuss the orientation of its parts.

The term **anterior** refers to the front surface of a body. **Ventral** and anterior are synonymous for the standing human but have different meanings for a quadruped. The ventral aspect of a standing dog includes its abdominal wall, which is directed toward the ground. The anterior of the same dog would be the portion including the face.

The opposite of anterior is **posterior**, meaning toward the back. For those of us who walk on two feet “posterior” and “**dorsal**” both refer to the same region of the body. The posterior aspect of a four-footed animal differs from that of humans. Thus, you may refer to a muscle running toward the anterior surface, or a structure having a specific landmark in the posterior aspect. These terms are body-specific: Regardless of the position of the body,

anterior: L., front

ventral: pertaining to the belly or anterior surface

posterior: toward the rear

dorsal: pertaining to the back of the body

The term quadruped refers to four-footed animals. The term biped refers to two-footed animals.

rostral: L., rostralis, beak-like

peripheral: relative to the periphery or away from

superficial: on or near the surface

deep: further from the surface

external: L., externus, outside

internal: within the body

distal: away from the midline

proximal: L., proximus, next to

prone: body in horizontal position with face down

supine: body in horizontal position with face up

lateral: toward the side

flexion: L., flexio, bending

extension: Gr., ex, out; L., tendere, to stretch

hyperextension: extreme extension

dorsiflexion: flexion that brings dorsal surfaces into closer proximity (syn., hyperextension)

plantar: pertaining to the sole of the foot

plantar flexion: flexion of toes of the foot

inversion: L., in, in; versio, to turn

eversion: L., ex, from, out; versio, to turn

palmar: pertaining to the palm of the hand

anterior is toward the front of that body. The term **rostral** is often used to mean toward the head. If the term is used to refer to structures within the cranium, rostral refers to a structure anterior to another.

When discussing the course of a muscle, we often need to clarify its orientation with reference to the surface or level within the body. A structure may be referred to as **peripheral** (away from the center) to another. A structure is **superficial** if it is confined to the surface.

When we say one organ is “**deep** to” another organ, we mean it is closer to the axis of the body. A structure may also be referred to as being **external** or **internal**, but these terms are generally reserved for cavities within the body. You may refer to an aspect of an appendicular structure (such as arms and legs) as being **distal** (away from the midline) or **proximal** (toward the root or attachment point of the structure).

A few terms refer to the actual present position of the body rather than a description based on the anatomical position. **Superior** (above, farther from the ground) and **inferior** (below, closer to the ground) are used in situations in which gravity is important. Superior can also indicate relative location. Structures that are near the head are referred to as superior or cranial, while those near the feet are referred to as inferior or caudal (the term *caudal* is more often used in this context when referring to an embryo). The terms **prone** (on the belly) and **supine** (on the back) are also commonly used in describing the present actual position.

Often we need to describe the orientation of a structure relative to another structure. Some useful terms are **lateral** (related to the side) and **medial** (toward the median plane). If a point is closer to the median plane (the one that divides the body into left and right halves), it is medial to a point that is farther from that plane, which is lateral. So you would say, for instance, that the tongue is medial to the molars in the mandible because it is closer to the midline or median plane.

Terms of Movement

There are specialized terms associated with movement. **Flexion** refers to bending at a joint, usually toward the ventral surface. Flexion usually results in two ventral surfaces coming closer together. **Extension** is the opposite of flexion, being the act of pulling two ends farther apart. **Hyperextension**, or extending a joint too far, is sometimes referred to as **dorsiflexion**.

Use of flexion and extension with reference to feet and toes is a little more complex. **Plantar** refers to the sole of the foot, the flexor surface. If you rise on your toes, you are extending your foot, but the gesture is referred to as **plantar flexion** because you are bringing ventral surfaces closer together. A **plantar grasp reflex** is one in which stimulation of the sole of the foot causes the toes of the feet to “grasp.” The term *dorsiflexion* may be used to denote elevation of the dorsum (upper surface) of the foot. You may turn the sole of your foot inward, termed **inversion**. A foot turned out is in **eversion**.

The term **palmar** refers to the palm of the hand, that is, the ventral (flexor) surface. The side opposite the palmar side is the dorsal side. If the

hand is rotated so that the palmar surface is directed inferiorly, it is **pronated** (remembering that in the prone position, one is lying on the stomach or ventral surface). **Supination** refers to rotating the hand so that the palmar surface is directed superiorly. A **palmar grasp reflex** is elicited by lightly stimulating the palm of the hand. The response is to flex the fingers to grasp. These and other useful terms and their definitions may be found in Appendixes A and B and the Glossary at the end of the book, as well as in a good medical dictionary.

The names of muscles, bones, and other organs were mostly set down at a time in history when medical people spoke Latin and Greek as universal languages. The intention was to name parts unambiguously rather than to make things mysterious. Many of the morphemes left over from Latin and Greek are worth learning separately. When you come across a new term, you will often be able to determine its meaning from these components. For instance, when a text mentions an **ipsilateral** course for a nerve tract, you can see **ipsi** (same) and lateral (side) and conclude that the nerve tract is on the same side as something else. Your study of the anatomy and physiology of the human body will be greatly enhanced if it includes memorization of some of the basic word forms found in the appendixes.

While you are studying the nomenclature of the field, do not let the plurals get you down. Fortunately, Latin is a well-organized language with a few general rules that will assist you in sorting through terminology. If a singular word ends in *a*, the plural will most likely be *ae* (*pleura*, *pleurae*). If a word ends in *us* (such as *locus*), the plural will end in *i* (*loci*). When the singular form ends in *um* (as in *datum* or *stratum*), the plural ending will change to *a* (*data* or *strata*).

Often you can feel comfortable using the Anglicized version (*hiatuses*), but do not assume everyone will. Many combined forms involve a possessive form, denoting ownership (the genitive case, in linguistic jargon): *corpus*, body; *corporum*, of the body. The English pronunciation of these forms is unfortunately less predictable and not universally adopted.

Parts of the Body

The human body can be described in terms of specific regions. The **thorax** is the chest region, and the **abdomen** is the region represented externally as the belly, or anterior abdominal wall. Together, these two components make up the **trunk** or **torso**. The **dorsal trunk** is the region we commonly refer to as the *back*. The area of the hip bones is known as the **pelvis**. Resting atop the trunk is the head or **caput**.

The skull consists of two components: the **cranial portion**, the part of the skull that houses the brain and its components, and the **facial part**, the part of the skull that houses the mouth, pharynx, nasal cavity, and structures related to the upper airway and mastication (chewing).

The upper and lower extremities are attached to the trunk. The **upper extremity** consists of the arm (from the shoulder to the elbow), the forearm, wrist, and hand. The **lower extremity** is made up of the thigh, leg, ankle,

pronated: to place an organism in the prone position

supination: to place an organism in the supine position

ipsi: same

thorax: the part of the body between the diaphragm and the seventh cervical vertebra

abdomen: L., belly

dorsal trunk: the region commonly referred to as the back of the body

pelvis: the area formed by the bones of the hip area

cranial portion: the part of the skull that houses the brain and its components

facial part: the part of the skull that houses the mouth, pharynx, nasal cavity, and structures related to the upper airway and mastication

upper extremity: portion of the body made up of the arm, forearm, wrist and hand

lower extremity: portion of the body made up of the thigh, leg, ankle, and foot

and foot. (In common usage, *arm* means from shoulder to hand and *leg* from thigh to foot.)

Within these components of the body are five enclosed spaces, or cavities, within which organs reside. Specific neuroanatomical cavities include the cranial cavity, in which the brain resides, and the vertebral canal, within which is found the spinal cord. Within the trunk are found the thoracic cavity (housing lungs and related structures), the pericardial cavity (housing the heart), and the abdominal cavity (housing the digestive organs).

To summarize:

- The **axial skeleton** consists of the trunk and head, whereas the **appendicular skeleton** comprises the upper and lower extremities.
- The **trunk** consists of the abdominal and thoracic regions.
- Anatomical terminology is the specialized set of terms used to define the position and orientation of structures.
- The **frontal plane** divides the body into front and back halves, whereas the **median** or **sagittal plane** divides the body into right and left halves. Sections that are parallel to these planes are referred to as **frontal sections** or **sagittal sections**, respectively.
- A **transverse section** divides the body into upper and lower portions.
- **Anterior** and **posterior** refer to the front and back surfaces of a body, respectively, as do **ventral** and **dorsal** for the erect human.
- **Superficial** refers to the surface of a body, while **peripheral** and **deep**, respectively, refer to directions toward and away from the surface.
- **Medial** refers to something closer to the median plane, while **lateral** refers to something farther from that plane.
- **Superior** refers to an elevated position, whereas **inferior** is closer to the ground.
- **Prone** and **supine** refer to being on the belly and back, respectively.
- **Proximal** refers to a point near the point of attachment of a free extremity or toward that point of attachment, and **distal** refers to a point away from the root of the extremity or away from that root.
- **Flexion** and **extension** refer to bending at a joint. Flexion refers to bringing ventral surfaces closer together, and extension is moving them farther apart.
- **Plantar** refers to the sole of the foot, while **palmar** refers to the palm of the hand. Both are ventral surfaces.

Building Blocks of Anatomy: Tissues and Systems

In the sections that follow, we present the building blocks of the physical system you are preparing to study. These blocks include the basic tissues, organs, structures made up of these tissues, and systems made up of the