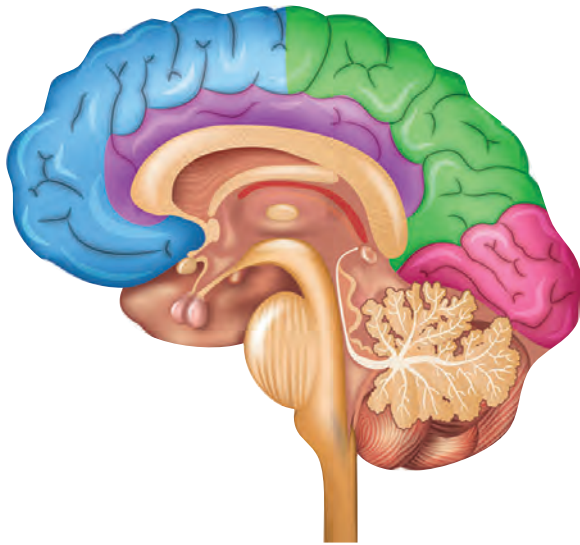


# **NEUROANATOMY AND NEUROPHYSIOLOGY**

for Speech and Hearing Sciences





# NEUROANATOMY AND NEUROPHYSIOLOGY

## for Speech and Hearing Sciences

J. ANTHONY SEIKEL, PhD • KOSTAS KONSTANTOPOULOS, PhD • DAVID G. DRUMRIGHT, BS





5521 Ruffin Road  
San Diego, CA 92123

e-mail: [information@pluralpublishing.com](mailto:information@pluralpublishing.com)  
website: <http://www.pluralpublishing.com>

Copyright © 2020 by Plural Publishing, Inc.

Typeset in 10/12 Minion Pro by Flanagan's Publishing Services, Inc.  
Printed in China by Spectrum Printing, LLC

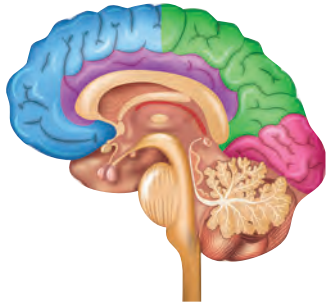
All rights, including that of translation, reserved. No part of this publication may be reproduced, stored in a retrieval system, or transmitted in any form or by any means, electronic, mechanical, recording, or otherwise, including photocopying, recording, taping, Web distribution, or information storage and retrieval systems without the prior written consent of the publisher.

For permission to use material from this text, contact us by  
Telephone: (866) 758-7251  
Fax: (888) 758-7255  
e-mail: [permissions@pluralpublishing.com](mailto:permissions@pluralpublishing.com)

*Every attempt has been made to contact the copyright holders for material originally printed in another source. If any have been inadvertently overlooked, the publishers will gladly make the necessary arrangements at the first opportunity.*

#### Library of Congress Cataloging-in-Publication Data

Names: Seikel, John A., author. | Konstantopoulos, Kostas, author. |  
Drumright, David G., author.  
Title: Neuroanatomy and neurophysiology for speech and hearing sciences / J.  
Anthony Seikel, Kostas Konstantopoulos, David G. Drumright.  
Description: San Diego, CA : Plural, [2020] | Includes bibliographical  
references and index.  
Identifiers: LCCN 2018021961 | ISBN 9781635500714 (alk. paper) | ISBN  
1635500710 (alk. paper)  
Subjects: | MESH: Speech—physiology | Hearing—physiology | Nervous  
System—anatomy & histology  
Classification: LCC QP306 | NLM WV 501 | DDC 612.7/8—dc23  
LC record available at <https://lcn.loc.gov/2018021961>



# CONTENTS

<i>Preface</i>	<i>xiii</i>
<i>Acknowledgments</i>	<i>xv</i>
<i>Contributors</i>	<i>xvii</i>
<i>Reviewers</i>	<i>xix</i>
<i>About the Authors</i>	<i>xxi</i>

<b>1</b>	<b>INTRODUCTION AND OVERVIEW</b>	<b>1</b>
	Overview of the Nervous System	2
	Divisions of the Nervous System	7
	Autonomic Nervous System	7
	Somatic Nervous System	7
	Developmental Organization	8
	Development	8
	Terminology Related to Neuroanatomy and Neurophysiology	16
	Terms of Movement	17
	Terms of Neuropathology in Speech-Language Pathology	18
	Chapter Summary	19
	Case Study 1–1	21
	Case Study 1–2	24
	References	28

<b>2</b>	<b>NEURONS AND GLIAL CELLS</b>	<b>31</b>
	Introduction	31
	Neurons	31
	Cellular Components of the Soma	32
	Gross Structure of the Neuron	33
	Soma	33
	Dendrites	34
	Axons	34
	Neuronal Cell Types	34
	Classification Based on Number of Dendrites	34
	Classification Based on Dendrite Arborization	34
	Classification Based on Axon Length	36
	Classification Based on Conduction Velocity	36
	Classification Based on Functional Connection	36

Glial Cells	37
Oligodendrocytes and Schwann Cells	40
Radial Glia	41
Satellite Cells and Enteric Glial Cells	41
Ependymal Cells	41
Action Potential	41
The Physical Synapse	42
Stimulation of a Neuron	42
Generating the Action Potential	44
<i>Ion Channels and Gradients</i>	44
<i>Resting State</i>	44
<i>Stimulation</i>	45
<i>Generation of the Action Potential</i>	45
<i>Propagation</i>	45
Communication Across the Synapse	47
Excitation and Inhibition	47
Summation	48
Neurotransmitters	48
Chapter Summary	51
Case Study 2–1	52
References	60

<b>3 BASIC REFLEX AND SENSORY FUNCTION: HOW WE KNOW THE WORLD</b>	<b>61</b>
Introduction	61
The Spinal Reflex Arc	61
Golgi Tendon Organs	65
Other Sensation and Sensors	65
Somatosensors	65
Representation of the Somatic Sensation in the Spinal Cord	68
Special Senses	69
Visual Sensation	69
Olfactory Sensation	71
Gustatory Sensation	71
Auditory Sensation	72
Vestibular Sensors	73
Chapter Summary	74
References	80

<b>4 CEREBRAL CORTEX</b>	<b>81</b>
Introduction	81
General Structures and Landmarks of the Cerebral Cortex	85
Major Sulci and Fissures	85
Meningeal Linings	89
The Ventricles and Cerebrospinal Fluid	90
<i>Circulation of CSF</i>	93
Cell Types of the Cerebral Cortex	93
Layers of the Cerebral Cortex	94
Lobes of the Cerebral Cortex	100

Frontal Lobe	100
Parietal Lobe	104
Temporal Lobe	104
Occipital Lobe	106
Insula or Insular Cortex	106
Limbic System	107
Medial Surface of the Cerebral Cortex	107
Inferior Surface of the Cerebral Cortex	108
Posterior-Inferior (Ventral) Cerebral Cortex	108
Anterior-Inferior Cerebral Cortex	108
Myelinated Fibers	109
Projection Fibers	109
<i>Corticobulbar and Corticospinal Tracts</i>	110
<i>Corticobulbar Tract</i>	111
<i>Corticospinal Tract</i>	111
Association Fibers	111
Commissural Fibers	112
The Other Half: Hemispheric Specialization	113
Chapter Summary	118
Case Study 4–1	119
Case Study 4–2	121
Case Study 4–3	123
Case Study 4–4	125
References	133

## **5 ANATOMY OF THE SUBCORTEX 137**

Introduction	137
Basal Ganglia	137
Hippocampus	143
Diencephalon	145
Thalamus	145
Epithalamus	145
Subthalamus	145
Hypothalamus	145
Chapter Summary	148
Case Study 5–1	149
Case Study 5–2	153
Case Study 5–3	156
References	161

## **6 ANATOMY OF THE BRAINSTEM 163**

Introduction	163
Superficial Brainstem Landmarks	163
Superficial Medulla Oblongata	163
Superficial Pons	167
Superficial Midbrain	167
Deep Structures of the Brainstem	167

Deep Structures of the Medulla Oblongata	167
Deep Structures of the Pons	172
Deep Structures of the Midbrain	176
<b>Auditory Pathway</b>	<b>179</b>
Cochlear Nucleus	179
Superior Olivary Complex	179
Inferior Colliculus	180
Lateral Lemniscus	182
Medial Geniculate Body	182
<b>Auditory Reception at Temporal Lobe</b>	<b>182</b>
Efferent Pathways	184
Vestibular Pathway	184
Acoustic Reflex	185
<b>Chapter Summary</b>	<b>185</b>
<b>Case Study 6–1</b>	<b>186</b>
<b>References</b>	<b>192</b>

<b>7 THE CRANIAL NERVES</b>	<b>193</b>
Introduction	193
Cranial Nerve Classification	193
General Somatic Afferent (GSA) Nerves	194
Special Somatic Afferent (SSA) Nerves	194
General Visceral Afferent (GVA) Nerves	194
Special Visceral Afferent (SVA) Nerves	194
General Visceral Efferent (GVE) Nerves	197
General Somatic Efferent (GSE) Nerves	197
Specific Cranial Nerves	198
I Olfactory Nerve (SVA)	198
II Optic Nerve (SSA)	198
Eye Movement: III Oculomotor Nerve (GSE, GVE), IV Trochlear Nerve (GSE), VI Abducens Nerve (GSE)	202
V Trigeminal Nerve (GSA, SVE)	204
VII Facial Nerve (SVE, SVA, GVE)	205
VIII Vestibulocochlear Nerve (SSA)	207
<i>Acoustic Branch</i>	208
<i>Vestibular Branch</i>	209
<i>Efferent Component</i>	211
IX Glossopharyngeal Nerve (GSA, GVA, SVA, GVE, SVE)	211
X Vagus Nerve (GSA, GVA, SVA, GVE, SVE)	212
XI Accessory Nerve (SVE)	214
XII Hypoglossal Nerve (GSE)	214
Chapter Summary	215
Case Study 7–1	216
Case Study 7–2	218
References	227

<b>8 CEREBELLAR ANATOMY AND PHYSIOLOGY</b>	<b>229</b>
Introduction	229
Structure of the Cerebellum	229



Cellular Structure of the Cerebellum	238
Nuclei of the Cerebellum	240
Fastigial Nucleus	241
Globose and Emboliform Nuclei	241
Dentate Nucleus	241
Tracts Serving the Cerebellum	242
Input to the Cerebellum	242
<i>Vestibulocerebellar Pathways</i>	242
<i>Dorsal Spinocerebellar Tract</i>	242
<i>Cuneocerebellar Tract</i>	242
<i>Ventral Spinocerebellar Tract</i>	242
<i>Rostral Spinocerebellar Tract</i>	242
<i>Pontocerebellar Tract</i>	243
<i>Olivocerebellar Tract</i>	244
Cerebellar Peduncles	244
<i>Superior Cerebellar Peduncle</i>	245
<i>Middle Cerebellar Peduncle</i>	245
<i>Inferior Cerebellar Peduncle</i>	246
Cerebellum and Motor Control	247
Chapter Summary	248
Case Study 8–1	249
Case Study 8–2	253
Case Study 8–3	257
References	263

## 9

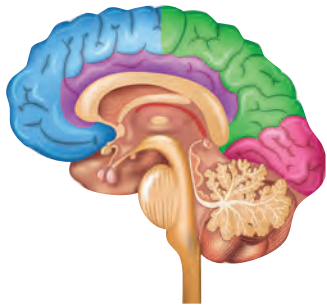
**SPINAL CORD AND PATHWAYS****265**

Introduction	265
Vertical Anatomy of the Spinal Cord	266
Transverse Anatomy of the Spinal Cord	270
Pathways of the Spinal Cord	273
Ascending Pathways	276
<i>Posterior Funiculus: Fasciculus Gracilis and Fasciculus Cuneatus</i>	276
<i>Anterior Funiculus: Anterior and Lateral Spinothalamic Tracts</i>	278
<i>Lateral Funiculus</i>	278
<i>Anterior and Posterior Spinocerebellar Tracts</i>	278
Descending Pathways	278
Pyramidal Pathways	278
<i>Corticospinal Tract</i>	278
<i>Corticobulbar Tract</i>	281
Other Descending Pathways	283
<i>Extrapyramidal System</i>	283
<i>Corticostriate Pathway</i>	284
<i>Corticothalamic Fibers</i>	285
<i>Corticopontocerebellar Fibers</i>	285
Chapter Summary	285
Case Study 9–1	286
Case Study 9–2	289
References	295

<b>10</b>	<b>CEREBROVASCULAR SUPPLY</b>	<b>297</b>
	Introduction	297
	Carotid Artery Supply	297
	External Carotid Artery Supply	297
	Internal Carotid Artery Supply	303
	<i>Anterior Cerebral Artery</i>	304
	<i>Posterior Communicating Artery</i>	304
	<i>Middle Cerebral Artery</i>	304
	Vertebrobasilar System	307
	Vertebral and Basilar Arteries	307
	Posterior Cerebral Artery	307
	Venous Drainage of the Cerebrovascular Supply	307
	Chapter Summary	309
	Case Study 10–1	310
	References	318
<b>11</b>	<b>NEURAL CONTROL OF SPEECH AND SWALLOWING</b>	<b>319</b>
	Introduction	319
	Neural Control of Speech	319
	Feedback and Correction	319
	Models of Speech Production	321
	Neural Control of	
	Mastication and Deglutition	322
	Development of Swallowing Function	322
	Adult Patterns of Mastication and Deglutition	323
	Oral Stage	323
	Pharyngeal Stage	324
	Relaxation of the Upper Esophageal Sphincter	326
	Esophageal Stage	326
	Reflexes and Their Integration into Central Pattern Generators	327
	Oral Stage Reflexes	327
	<i>Chewing Reflex</i>	327
	Pharyngeal Stage Reflexes	327
	<i>Vomit Reflex</i>	327
	<i>Cough Reflex</i>	328
	Reflexes of Respiration and Apnea	328
	Sensation in Mastication and Deglutition	328
	Sensation	328
	Gustation	328
	Olfaction	330
	Tactile, Proprioceptive, and Thermal Sensation	330
	Complex Motor Responses	330
	Chapter Summary	331
	Case Study 11–1	332
	Case Study 11–2	335
	Case Study 11–3	337

Case Study 11–4	339
References	345
<i>Appendix. Answers to Study Questions</i>	347
<i>Glossary</i>	357
<i>Index</i>	373





# PREFACE

**T**he study of the brain and its functions is at the heart of communication sciences and its disorders. While there are many neurological conditions that immediately come to mind when we think of maladies affecting the brain, the nervous system is intrinsically involved in most of the activities of our field, from the cognitive and motoric aspects of phonology or the impact of myelination on normal language development to (central) auditory processing disorder. All human actions arise from processes of the nervous system, and we can trace many of the deficits treated in our professions to some type of failure affecting this nervous system.

It is with this understanding that we sought to create this textbook and study materials. Neuroscience is the study of what is arguably the most complex phenomenon in the known universe, the nervous system. We, as humans, have brains that are uniquely complex in structure and, most importantly, in function. The human brain has evolved to work in complex networks that entrain multiple areas of the brain, giving it a capacity for problem solving that outstrips our nearest evolutionary neighbors.

As audiologists, speech-language pathologists, and speech and hearing scientists we are in a position to see the inner workings of the brain firsthand through the many neuropathologies with which we are presented. The basal ganglia circuits are uniquely revealed in the tremor, hyperkinesia, and hypokinesia of conditions such as Parkinson's disease, Huntington's disease, or hepatolenticular degeneration. The impact of disease conditions such as multiple sclerosis on hearing function, cognition, and speech production can provide evidence for site of lesion activity if we are able to recognize the signs and symptoms related to the brain region affected. We are challenged on a daily basis to provide meaningful therapy to individuals who have suffered cerebrovascular accident or trauma, and we must work to provide treatment to help overcome the life-changing effects of those lesions. To do this requires a deep knowledge of this extraordinarily complex nervous system but also requires that the clinician develop the intention to continually learn about the nervous system and new treatments that emerge. As an example, behavioral treatments are emerging that have been shown to differentially increase the brain volume and function in areas shown to be active during attention activi-

ties, expression of compassion, and awareness of others (theory of mind). Therapies directed toward these dysfunctions could directly affect the lives of those with right hemisphere dysfunction, and the wise clinician will keep a close eye on developments such as these. To do this requires knowledge, desire, and intention. It is our deep hope that these materials can provide at least some of the motivation for a lifetime of study in neuroscience. A central component of this text is the Neuroquest software. We owe a deep debt of gratitude to Dr. Sadanand Singh, who, many years ago as our first publisher of another book, insisted that study software was a critically important component of any text. Now, 20 years later, we are pleased and humbled to continue with his charge to make the current textbook as powerful a learning tool as we can.

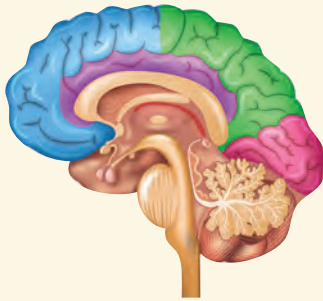
The purpose of this textbook is to help the undergraduate and graduate student of speech-language pathology learn about the structure and function of the brain. This knowledge will aid not only in accurate clinical diagnosis but also in the correct use of evidence-based practice methods for speech therapy. There are many neurological diseases in which the primary signs and symptoms are within the domains of speech, language, or hearing disorders, so there is fertile ground for application of the knowledge acquired through study of neuroscience. We have included a number of clinical cases at the end of each chapter to prime the student's problem-solving clinical skills in his or her future profession. Most of the cases include neurological assessments that were performed over the course of treatment (sometimes even 10 years after initial neurological diagnosis), which we have included to help the reader recognize the timing of the speech/language disorder as related to the timing of the other neurological symptomatology.

This textbook is divided into 11 chapters. Chapter 1 briefly overviews the nervous system, starting from embryonic development to aging and including disorders of speech and language that the students in audiology and speech-language pathology need to be aware of. Chapters 2 and 3 discuss the structure and function of cellular components of the central nervous system, including how the signals are propagated (Chapter 2) and the function of basic reflexes (Chapter 3). Chapter 4 discusses the cerebral cortex, including landmarks and components and their relation to our disciplines. Chapters 5 and 6 discuss areas and structures

beneath the cortex (subcortex), including the basal ganglia, hippocampus, thalamus (Chapter 5), brainstem (Chapter 6), as well as their associated connections to the cortex. Chapter 7 is dedicated to presentation of the cranial nerves, many of which are critical to hearing and speech. Chapters 8 and 9 discuss the cerebellum, the spinal cord, and their fiber connections. Chapter 10 focuses on the cerebrovascular supply to the brain, elaborating on the vascular supply critical for speech, language, and hearing. Chapter 11 aims to provide to the student the knowledge about the function for the neural control of speech and swallowing, including theoretical models of speech production.

J. Tony Seikel is co-author of two textbooks in anatomy and physiology of speech, hearing, and language and has taught neuroscience and neurogenic coursework for 30 years. Kostas Konstantopoulos is an assistant professor in the European University Cyprus and teaches all neurogenic courses

and neuroanatomy. He currently serves as the coordinator for the Bachelor's degree of Speech and Language Therapy and is the coordinator for the Master's degree in Speech Language Pathology. He has extensive clinical and research experience in neurogenic communication disorders spanning 15 years. For the past 6 years he has provided clinical assessment and treatment of speech and dysphagia at the Cyprus Institute of Neurology and Genetics (CING). The majority of the case histories utilized in the chapters have been drawn from his files and referred from all four neurology clinics in the Cyprus Institute of Neurology and Genetics. David Drumright is co-author of two textbooks in anatomy and papers on pedagogy, and has developed software for study of anatomy (*Anima* and *Anatesse* for anatomy and physiology, *Audin* for auditory physiology, and now *Neuroquest* for study of neuroscience).



### Learning Outcomes for Chapter 10

- Identify the two major sources of vascular supply to the brain.
- Identify the major arteries arising from the vertebrobasilar and carotid supplies and the regions of the brain being served by those arteries.
- Discuss the hypothesized function of the circle of Willis.
- Identify the deep arteries and branches supplying each lobe and surface of the brain as well as the brainstem, spinal cord, cerebellum, basal ganglia, and thalamus.
- Discuss the potential effects of loss of supply to any of the major branches of the vertebrobasilar or carotid supplies.

# 10

# CEREBROVASCULAR SUPPLY

## INTRODUCTION

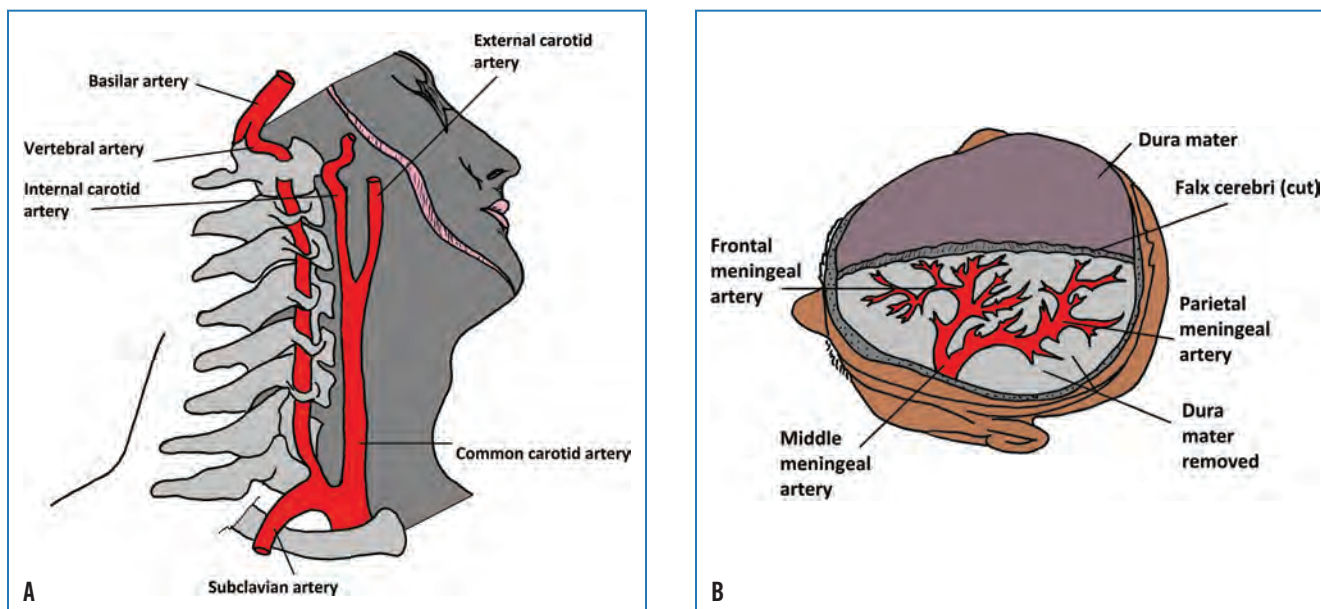
The brain is a metabolic giant. While it makes up only 2% of the body's weight, it utilizes 20% of the oxygen of the body! Ischemia (cessation of blood flow) can result in irreversible brain damage within minutes, so a steady supply of blood is essential to the health of the brain. As we will see, the human brain has several redundant features that have the effect of partially protecting the brain from loss of nutrients. It is important for us as speech-language pathologists and audiologists to become well versed in the vasculature of the brain because the damaged brain tissues caused by either ischemia or hemorrhage (ruptured blood vessels) will affect hearing, language, speech, and cognition, causing such disorders as cortical deafness aphasia, apraxia, and dysarthria.

The vascular supply to the brain arises from two major sources: the carotid and vertebrobasilar systems. The dorsal aorta with its ascending and descending branches supplies the head and neck with blood. The branches of the aorta include the left brachiocephalic trunk, the left and right common carotid arteries, and the left and right subclavian arteries. The **common carotid arteries** give rise to the external and internal carotid arteries (Figure 10–1), while the vertebral arteries give rise to the basilar artery, posterior cerebral artery, and cerebellar arteries (Figure 10–2). We'll discuss the cerebrovascular supply based on these two major systems. You may wish to refer to the arterial territories schematically illustrated in Figures 10–2 C–F and Table 10–1 as we discuss them.

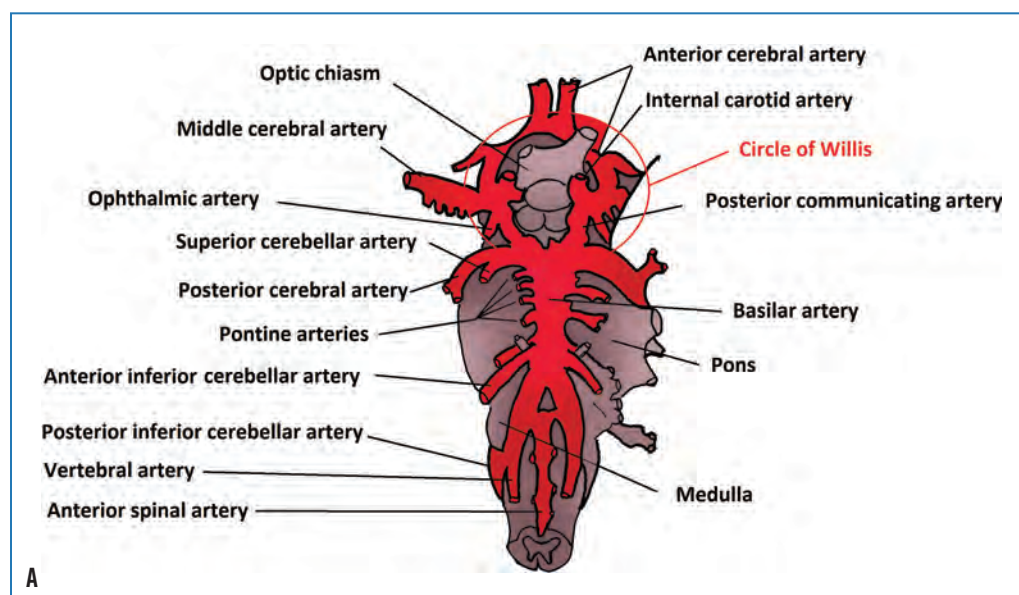
## CAROTID ARTERY SUPPLY

### External Carotid Artery Supply

While our focus will be on the internal carotid artery, the external carotid requires some attention as well. The **external carotid arteries** (see Figure 10–1) deliver blood to the cervical and facial soft tissues, the external ear, the sinonasal cavity of the skull, and the soft tissues of the scalp. The important **middle meningeal branch** (Figure 10–1B) of the external carotid arteries provides blood to the meninges of the brain by way of the **meningeal arteries** in the area superficial to the dura mater.

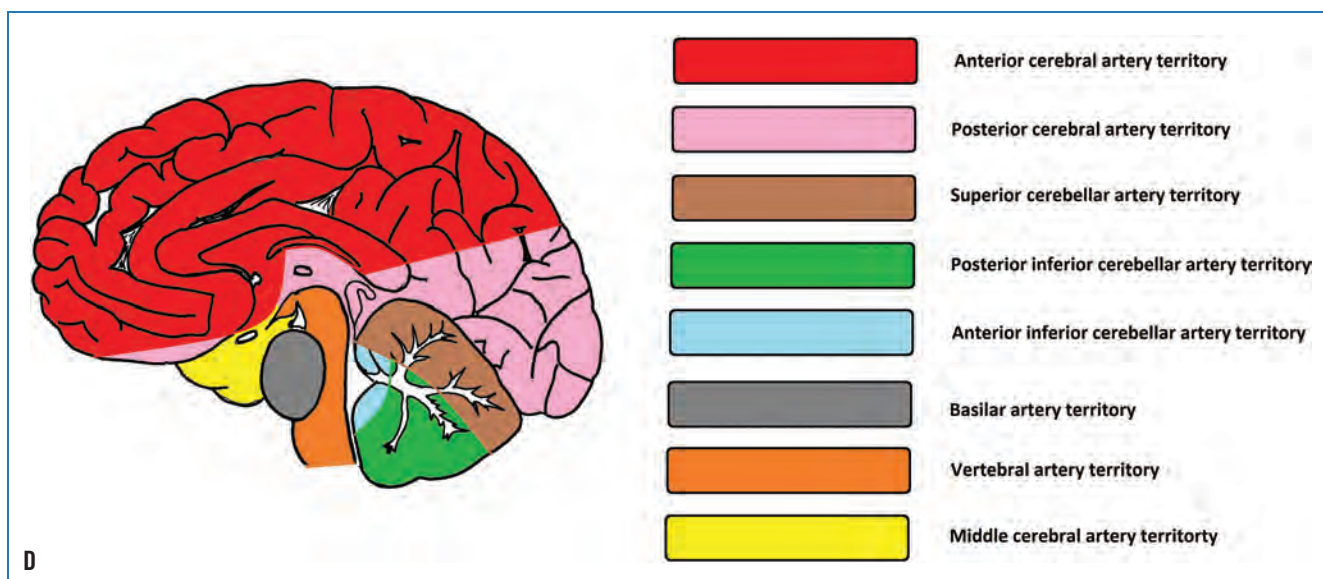
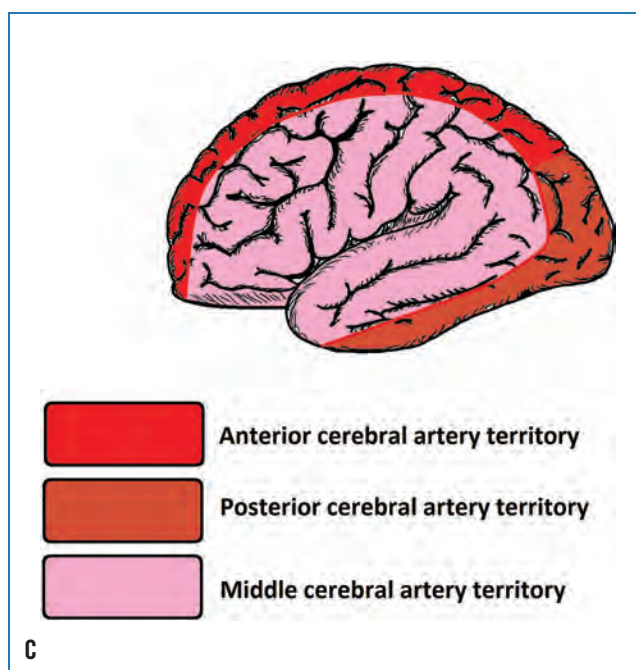
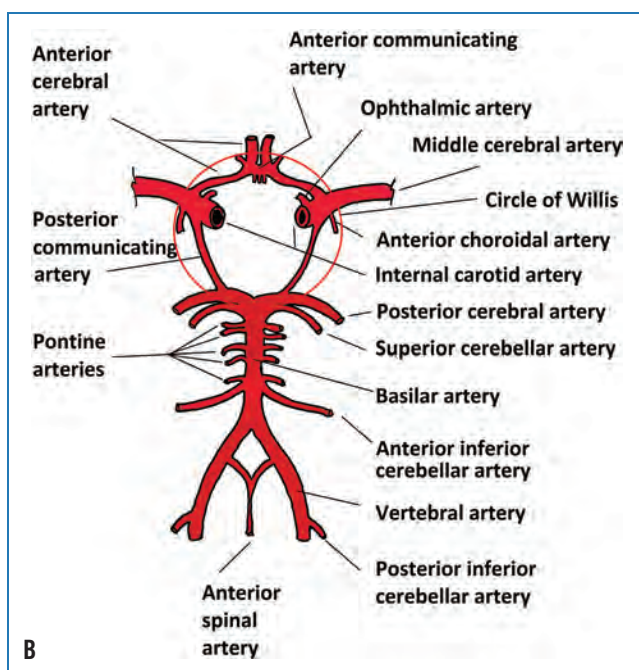


**FIGURE 10-1.** **A.** Vertebralis sources. The aorta gives rise to the common carotid artery as well as the vertebral artery. The common carotid artery bifurcates into the external and internal carotid supplies. The internal carotid artery enters the brain case, dividing into the middle cerebral and anterior cerebral arteries. The vertebral artery enters the brain case, anastomoses into the basilar artery, and gives rise to the posterior cerebral artery and cerebellar arteries. The internal carotid supply and the vertebralis supply are connected by means of the circle of Willis. **B.** Anterior and middle meningeal arteries.

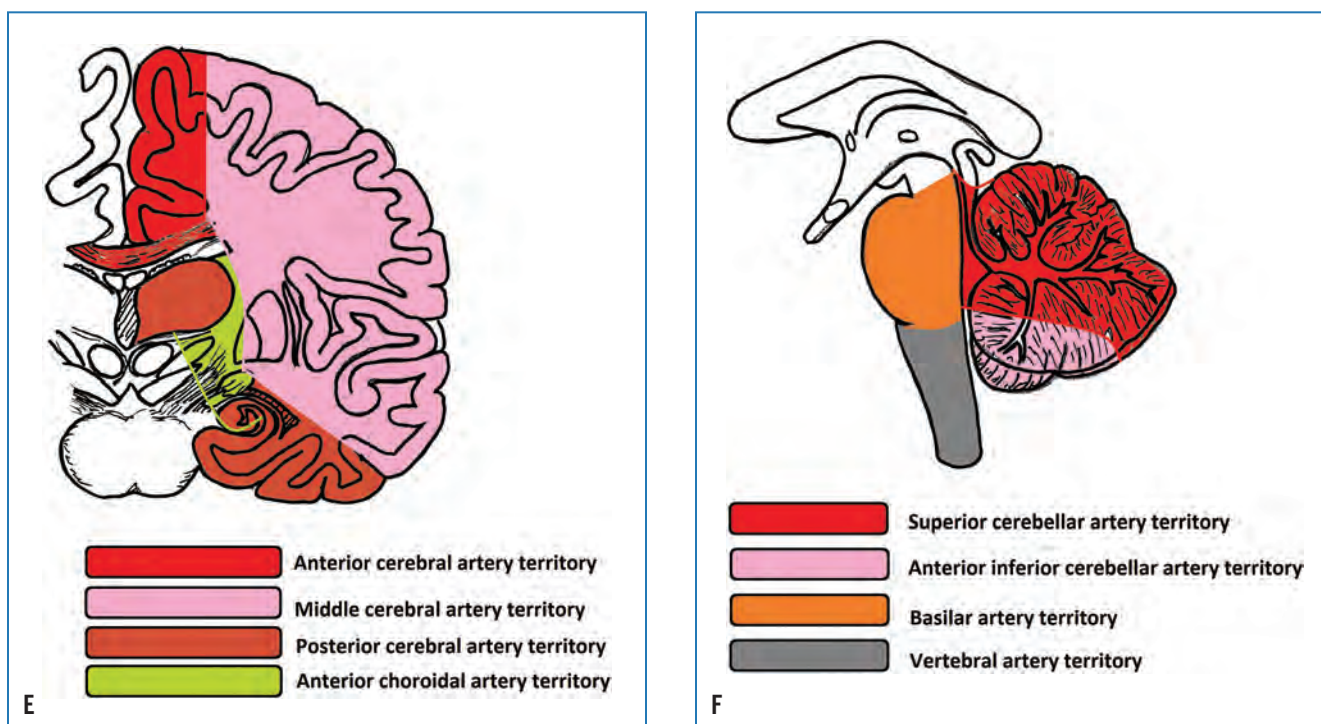


**FIGURE 10-2.** **A.** Carotid and vertebralis supplies from ventral surface of cerebral cortex.  
*continues*





**FIGURE 10-2.** *continued* **B.** Schematic of vascular supply showing major components. Note that circled area indicates location of circle of Willis. **C.** Arterial coverage of the lateral cerebral cortex. **D.** Medial cerebral cortex. *continues*



**FIGURE 10-2.** *continued* **E.** Internal cerebrum (coronal section). **F.** Brainstem and cerebellum.

**TABLE 10–1. Major Arteries of Cerebrovascular System and Areas Supplied**

Internal carotid supply	Major artery	Gives rise to	Serves
	Anterior cerebral artery		Corpus callosum
		Medial orbitofrontal a.	Gyrus rectus, olfactory bulb
		Frontopolar a.	Medial and lateral of anterior superior frontal gyrus
		Callosomarginal a.	Cingulate gyrus and sulcus
		Anterior, posterior and middle internal frontal branch of callosomarginal	Posterior of superior frontal gyrus and medial frontal lobe to precentral gyrus
		Pericallosal a.	Sulcus between corpus callosum and cingulum
		Paracentral a.	Superior precentral and postcentral gyri and paracentral lobule
		Precuneal artery	Anterior precuneus and superior parietal lobe
		Anterior communicating a.	Communication between left and right anterior cerebral arteries
		Recurrent a. of Heubner	Anterior/inferior head of caudate, putamen, anterior limb of internal capsule
		Inferior branches	Optic nerves and chiasm
		Superior branches	Anterior hypothalamus, septum pellucidum, anterior commissure, fornix, anterior/inferior corpus striatum
	Middle cerebral artery		
		Medial lenticulostriate a.	Outer globus pallidus
		Lateral lenticulostriate a.	Putamen, superior internal capsule and adjacent corona radiata, caudate nucleus
		Lateral frontobasal (orbitofrontal) a.	Inferior frontal gyrus
		Lateral frontobasal (orbitofrontal) a.	Lateral orbit and inferior frontal gyri
		Prefrontal a.	Operculum, pars triangularis, inferior frontal gyrus
		Ascending frontal (candelabra) a.	
		Anterior parietal a.	Intraparietal sulcus
		Posterior parietal a.	Posterior parietal lobe

*continues*

**TABLE 10–1.** *continued*

Internal carotid supply	Major artery	Gives rise to	Serves
		Precentral (prerolandic) a.	Posterior/middle of inferior frontal gyri, inferior lateral precentral gyrus
		Central (Rolandic) a.	Posterior precentral gyrus and inferior postcentral gyrus
		Temporooccipital	Superior and inferior occipital gyri
		Temporopolar	Temporal pole and anterior temporal lobe
		Anterior temporal	Temporal pole and anterior temporal lobe
		Middle temporal	Superior and middle portions, temporal lobe
		Posterior temporal a.	Posterior temporal lobe, insula
		Anterior choroidal a.	Choroid plexus, optic chiasm, optic tract, internal capsule, lateral geniculate body, globus pallidus, tail of caudate, hippocampus, amygdala, substantia nigra, red nucleus, crus cerebri
Vertebrobasilar supply	Vertebral arteries	Anterior and posterior spinal arteries	Anterior and posterior spinal cord
		Posterior inferior cerebellar a.	Branches into anterior-inferior cerebellar and superior cerebellar branches
Vertebrobasilar supply	Basilar artery		
		Superior cerebellar a.	Upper surface of cerebellum; branches to serve anterior medullary velum, tela chorioidea of third ventricle
		Superior cerebellar a.	Upper surface of cerebellum
		Posterior communicating a.	Connects posterior cerebral and middle cerebral arteries
		Anterior inferior cerebellar a.	Anterior undersurface of cerebellum; gives rise to internal auditory a.
		Internal auditory a. (labyrinthine a.)	Arises from anterior inferior cerebellar artery; serves auditory and vestibular mechanism
		Pontine a.	Pons
		Posterior cerebral a.	Gives rise to thalamoperforating arteries, thalamogeniculate, peduncular perforating, medial posterior choroidal branch, lateral posterior choroidal branch



### The Meningeal Artery and Traumatic Brain Injury

The meningeal vessels, located in the sulci of the skull, are susceptible to penetrating traumatic brain injury (TBI). The middle meningeal artery, which covers a large portion of the skull, is frequently affected, with penetrating injury rupturing the artery and causing release of blood into the area above the dura mater (epidural hematoma). Clinically, the development of such a mass creates increased intracranial pressure and a concomitant herniation and swelling of the brain, with symptomatology involving speech, mobility, vision, and consciousness.

## Internal Carotid Artery Supply

The internal carotid arteries give rise to the anterior cerebral arteries, posterior communicating arteries, and middle cerebral arteries as well as a number of other smaller branches. For speech-language pathology and audiology, the middle cerebral artery (MCA) is extraordinarily important, as it serves all of the speech, language, and hearing territory of the brain.

(high blood pressure). Further, turbulence at the bifurcation of the common carotid artery increases the likelihood that plaques will become dislodged and become emboli that can lodge elsewhere within the bloodstream. The arterial supply mimics the branching in trees, with larger branches splitting into smaller branches at bifurcations, which then branch again to create even smaller branches. In the vascular supply, arteries give rise to arterioles, which give rise to capillaries, with each successive generation at a branching becoming smaller in diameter. The terminal point of this branching is the union of veins and arteries, with veins showing increasing diameter as the blood makes its way back to the heart for oxygenation. (This is why there are rarely problems with emboli in the venous system, although clots may enter the heart and cause significant problems there.) Thus, any foreign body in the arterial system has a high probability of lodging somewhere downstream of where it is released. The larger a floating clot is, the greater the area it will affect when it does lodge in the bloodstream. Doppler and magnetic arteriography are essential tools for the assessment of blood flow, as they provide a non-invasive and low cost means of determining the presence of plaques and restrictions before they cause ischemic events.



### Internal Carotid Artery Branching and Stroke

The internal carotid arteries and the vertebral arteries have tortuous bends and branching, which can lead to problems as we age. One of the most significant problem spots in the cerebrovascular system is at the point of **bifurcation** (dividing) of the common carotid artery into the internal and external carotid arteries. There is a significant narrowing at this branch in the artery, and if an **embolus** (floating blood clot) lodges at this location, it may starve the downstream tissue of oxygen. This is a critical emergency, since irreversible brain damage begins within five minutes of blood stoppage. In this case, blocking the entire internal carotid artery deprives blood to the anterior two-thirds of one entire cerebral hemisphere. An infarct covering this much of the MCA territory can result in profound aphasia if it involves the dominant hemisphere.

This is not the end of the problems with this bifurcation. Atherosclerotic plaques develop as we age as a result of diet, exercise level, and genetics. These plaques plaster themselves to the arterial walls, reducing the flexibility of the wall and thereby promoting hypertension



### Arterial Branches from the Carotid Supply

While we tend to focus on the anterior and middle cerebral arteries in our discussion of the carotid supply, it's worth reminding ourselves of other very relevant branches for speech-language pathologists and audiologists. The ophthalmic artery provides oxygenated blood to the eyeball, while the meningeohypophyseal artery supplies the pituitary gland. The inferolateral artery is very important, in that it supplies the III oculomotor, IV trochlear, and VI abducens nerves, and ischemia associated with this blood vessel can result in oculomotor paralysis (Capo, Kupersmith, Berenstein, Choi, & Diamond, 1991). The capsular arteries serve the internal capsule and the basal ganglia. Ischemia affecting the posterior limb of the internal capsule can result in severe paralysis due to the effect on the pyramidal pathway, although recovery can occur (Fries, Danek, Scheidtmann, & Hamburger, 1993), and involvement of the basal ganglia can result in motor control deficit (Boyd, Edwards, Siengsukon, Vidoni, Wessel, & Linsdell, 2009) and cognitive impairment (e.g., Seidel, Gronewold, Wicking, Bellebaum, & Hermann, 2016; Westmacott et al., 2017).



The posterior communicating artery is partially responsible for regulating blood flow and pressure within the cerebrovascular supply. Specifically, this artery connects the internal carotid and vertebrobasilar supplies, so that an occlusion in one supply can be compensated by the other supply. Occlusion of the posterior communicating artery threatens the ability of the circle of Willis to compensate for blood flow fluctuations (Liebeskind, 2003; Schomer et al., 1994). The anterior choroidal artery also serves the internal capsule (posterior limb), thalamus, and optic chiasm, so an infarct involving this artery can result in hemiplegia on the contralateral side of the body.

### Anterior Cerebral Artery

As seen in Figure 10–2A, the **anterior cerebral artery (ACA)** comprises a portion of the circle of Willis, coursing through the superior longitudinal fissure along the dorsal surface of the corpus callosum. The **circle of Willis** acts as a vascular backup system. Look at the schematic in Figure 10–2B, and first identify the basilar artery and then the internal carotid arteries so that you have located the two sources of blood for the brain. Now examine the way they are connected. The circle of Willis connects these two vascular supplies, and if the internal carotid artery supply is cut off due to infarct, the vertebrobasilar supply has the potential to supply those areas that are not receiving blood due to the infarct. The circle of Willis includes the anterior cerebral artery and the anterior and posterior communicating arteries. The anterior cerebral artery continues into the superior longitudinal fissure, serving the medial surface of the cerebral cortex, as well as a portion of the dorsal surface of the frontal and parietal lobes (Figures 10–3A, B, and C). The ACA is divided into three major segments. Section A1 includes the portion of the ACA within the circle of Willis and supplies blood to the basal ganglia, while A2 extends distally into the anterior two-thirds of the medial surface of the cerebral hemispheres to the genu of the corpus callosum. Segment A3 extends to the superior surface of the corpus callosum and supplies blood to the medial cerebral cortex.



#### Ischemia of the Anterior Cerebral Artery

A number of clinical signs arise from an infarction involving the anterior cerebral artery (ACA), depending on the anatomical sites involved, although collateral blood supply often reduces the signs of ACA blockage. The ACA serves the medial surface of the cerebral cortex, which supplies the areas controlling the legs. An infarct involving the ACA

can result in hemiplegia, particularly if the supplementary motor area is involved, as well as cortical sensory loss. With paralysis, a person may also find that inhibited reflexes are released and become active, including grasp and sucking reflexes. If the frontal pole, corpus callosum, and superior frontal gyrus are involved, the patient may have reduced ability to make decisions (hypobulia) or other cognitive involvement (Kang & Kim, 2008). Infarcts of the ACA are related to emotional lability, which is uncontrollable laughing or crying in absence of a relevant stimulus.

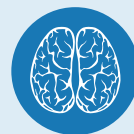### Posterior Communicating Artery

The **posterior communicating artery** sends collateral arterioles into the deep tissues of the brain, serving the thalamus, internal capsule, and optic tract. It gives rise to the **anterior choroidal artery**, which supplies the optic tract, posterior internal capsule, cerebral peduncles, medial temporal lobe, thalamus, and a portion of the corpus striatum.

### Middle Cerebral Artery

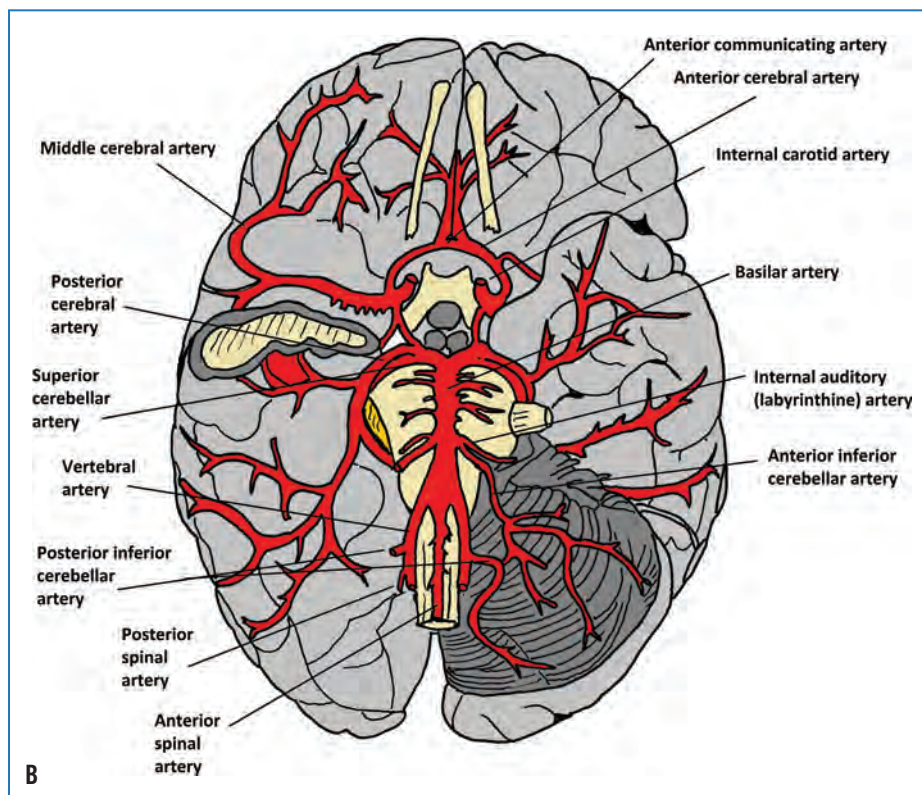
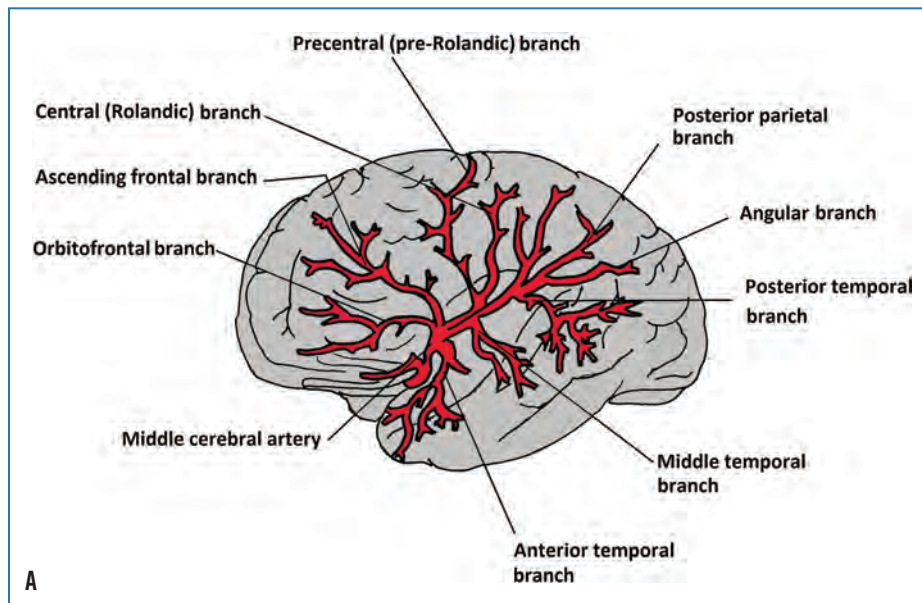
Because of the critical nature of the **middle cerebral artery (MCA)** to speech, language, and hearing, it requires some focused attention. The middle cerebral artery oxygenates the speech and language zones of the brain, including the suprolateral temporal as well as the lateral parietal and frontal lobes (see Figures 10–2 C–E and 10–3 A & B).

There are superficial and deep branches of the middle cerebral artery within the cortex. The **orbitofrontal** and **prefrontal superficial cortical branches** oxygenate the frontal lobe laterally and the frontal pole anteriorly. The posterior branches of the MCA (**parietal, angular, temporal, and occipital branches**) oxygenate the lateral surface of the frontal, parietal, occipital, and temporal lobes, including virtually all of the speech and language zones. The insular segment (also known as the Sylvian segment) supplies blood to the insular cortex and gives rise to the opercular segment, which serves the operculum, which is superficial to the insula. The many perforating branches provide blood to the caudate nucleus, the basal ganglia, and the internal capsule.

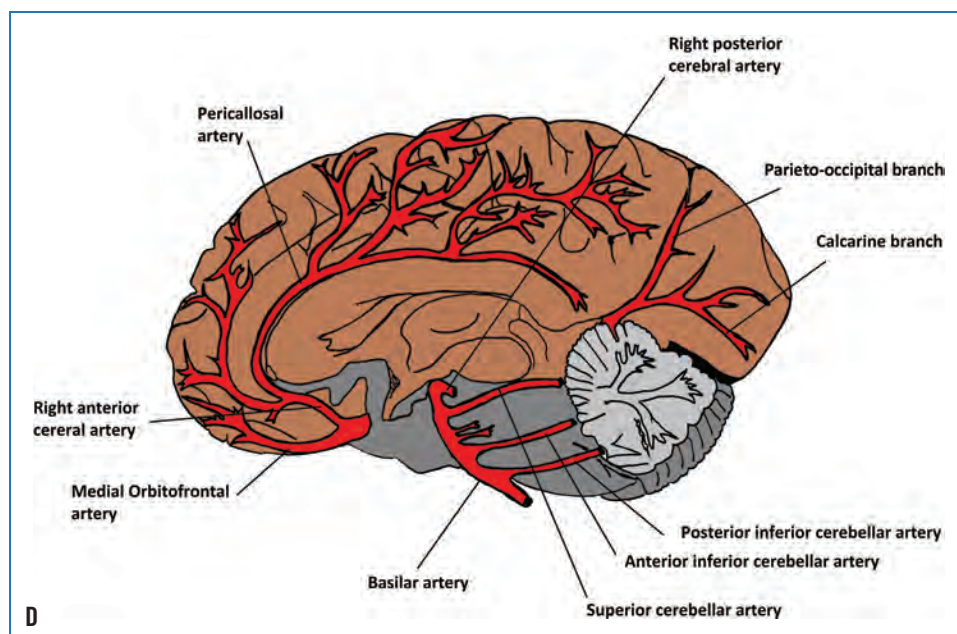
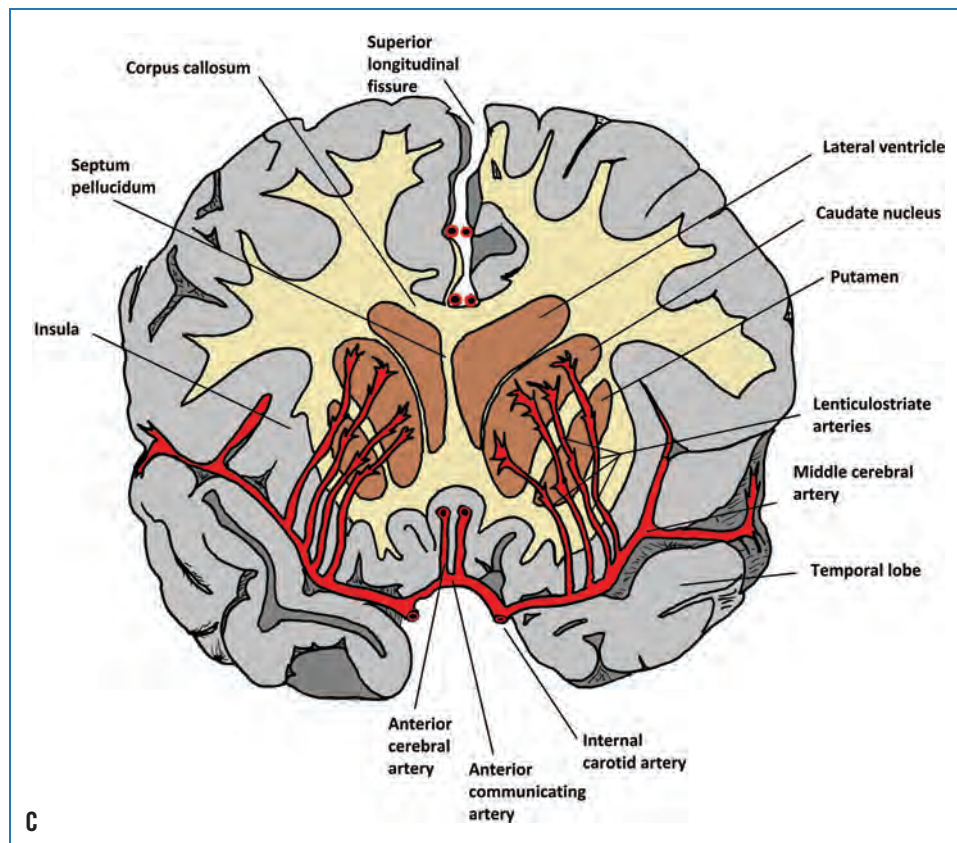


#### Infarcts of the Middle Cerebral Artery

Depending on the size of the infarct, lesions in the middle cerebral artery of the dominant hemisphere (typically the left hemisphere) will produce significant effects on motor function. One can expect upper motor hemiparesis on the right side, as well as a non-fluent or fluent aphasia, depending on the site of the lesion.



**FIGURE 10–3.** Views of the anterior and middle cerebral arteries. **A.** Lateral view of middle cerebral artery, showing its reach to the frontal, temporal, and parietal lobes. Note the proximity to the language (BA 40, 45, and 22) and cognition (BA 4, 46, and 10) areas. **B.** View of middle cerebral artery territory on inferior surface of the cortex. *continues*



**FIGURE 10–3.** *continued* **C.** Coronal section showing the middle cerebral artery serving the basal ganglia and thalamus. **D.** Medial view showing anterior cerebral artery.



Lesions in the insular and Sylvian fissure segments of the middle cerebral artery can affect Broca's area, Wernicke's area, and the precentral gyrus, resulting in aphasia, apraxia, and dysarthria. Infarct involving the insula can result in apraxia of speech, as well as loss of thermal sensation (Kodumuri et al., 2016). If the lesion extends to the cortical white matter beneath the insular cortex, one may see sensory disturbances, transcortical motor aphasia, phonatory deficiency, and dysphagia. A lesion in the area of the basal ganglia and internal capsule may create dysfunction in the direct and indirect pathways responsible for the initiation and control of movement, as well as dysfunction of the corticobulbar tract.

In summary, the brain uses a disproportionate volume of blood, and ischemia can result in irreversible brain damage within minutes.

- The vascular supply to the brain arises from two major sources: the carotid and vertebrobasilar systems. The common carotid arteries give rise to the external and internal carotid arteries, and the vertebral arteries give rise to the basilar artery, posterior cerebral artery, and cerebellar arteries.
- The external carotid arteries deliver blood to the cervical and facial soft tissues, the external ear, the sinonasal cavity of the skull, and the soft tissues of the scalp. The middle meningeal branch of the external carotid arteries provides blood to the meninges of the brain by way of the meningeal arteries in the area superficial to the dura mater.
- The internal carotid arteries give rise to the anterior and middle cerebral arteries as well as a number of other smaller branches. The middle cerebral artery is particularly relevant to speech-language pathologists and audiologists because of the territory it serves.
- The anterior cerebral artery courses through the superior longitudinal fissure along the dorsal surface of the corpus callosum. The anterior cerebral artery continues into the superior longitudinal fissure, serving the medial surface of the cerebral cortex, corpus callosum, a portion of the dorsal surface of the frontal and parietal lobes, and basal ganglia.
- The circle of Willis provides vascular redundancy to the blood supply to the brain. The circle of Willis includes the anterior cerebral artery and the anterior and posterior communicating arteries.
- The posterior communicating artery serves the thalamus, internal capsule, and optic tract.
- Superficial branches of the middle cerebral artery serve the superior temporal lobe, as well as the lateral and most of the dorsal surfaces of the frontal and parietal lobes, and the insula and operculum. Perforating branches serve the caudate nucleus, the basal ganglia, and the internal capsule.

## VERTEBROBASILAR SYSTEM

### Vertebral and Basilar Arteries

The **left and right vertebral arteries**, arising from the anterior vertebral column, join together (anastomose) to form the **basilar artery** at the junction of the pons and medulla in the brainstem (see Figures 10–2B and 10–3B). The vertebral and basilar arteries together deliver blood by means of large and small vessels in the posterior cerebrovascular circulation. Small arteries branch off of the vertebral arteries before the vertebral arteries combine to form the basilar artery. The posterior inferior cerebellar artery serves the base of the posterior cerebellum, while the anterior and posterior spinal arteries serve the spinal cord. The **perforating branches** of the vertebral arteries oxygenate the lower medulla, the upper cervical spinal cord, and the inferior cerebellar peduncles.

The **basilar artery** branches to serve posterior brain structures. The **pontine perforating artery** provides blood to the pons, midbrain, and cerebellar peduncles, while the **anterior inferior cerebellar artery** gives blood to the anterior cerebellar hemisphere, the pons, and the cerebellar peduncles. The anterior inferior cerebellar artery gives rise to the internal auditory artery (also known as the labyrinthine artery), which serves the auditory and vestibular mechanisms. The **superior cerebellar arteries** oxygenate the superior and lateral aspects of the cerebellar hemispheres, the superior cerebellar peduncle, and the superior cerebellar vermis.

### Posterior Cerebral Artery

The basilar artery gives rise to the left and right **posterior cerebral arteries** (see Figures 10–2A & B and 10–3B). As with the other arteries, the posterior cerebral arteries branch to form a number of smaller arteries that serve the cerebral cortex. The anterior temporal branch oxygenates the inferior surface of the temporal lobe, specifically the anterior fusiform gyrus and the uncus, while the posterior temporal artery oxygenates the posterior fusiform gyrus and the inferior temporal gyrus. The parietal branch serves the medial surface of the parietal lobe, including the cuneus and precuneus. The medial occipital branch serves the occipital lobe. The splenial branch serves the splenium of the corpus callosum, while the posterior medial choroidal branch oxygenates the choroidal plexus of the lateral and third ventricles, the thalamus and hypothalamus, and the posterior internal capsule and midbrain.

## VENOUS DRAINAGE OF THE CEREBROVASCULAR SUPPLY

A number of veins drain the cerebrum, cerebellum, and brainstem, subsequently emptying into the dural venous sinuses. Figure 10–4 shows the superficial venous system of the brain.